



Fig. 2. Web site of the Clinical Infostation.

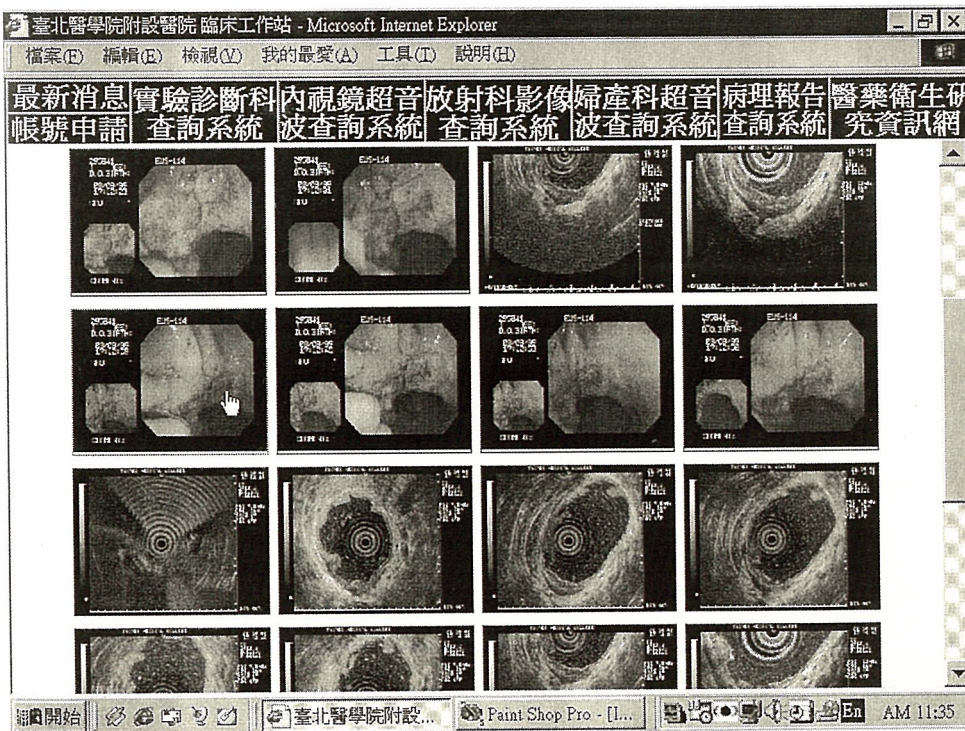


Fig. 3. Images of a case of gastric carcinoma detected by Endoscopic Ultrasonography (EUS) accessed through the Clinical Infostation.