

# Necrotizing Pneumococcal Pneumonia in Children: The Role of Pulmonary Gangrene

Yu-Chia Hsieh, MD,<sup>1</sup> Cheng-Hsiang Hsiao, MD,<sup>2</sup> Po-Nien Tsao, MD, PhD,<sup>3</sup> Jann-Yuan Wang, MD,<sup>4</sup> Po-Ren Hsueh, MD,<sup>5</sup> Bor-Luen Chiang, MD, PhD,<sup>3</sup> Wen-Sen Lee, MD,<sup>1</sup> and Li-Min Huang, MD, PhD<sup>3\*</sup>

**Summary.** Little is known about the mechanism of necrotizing pneumonia caused by *Streptococcus pneumoniae* in children. Pulmonary gangrene secondary to vascular thrombosis was reported in adults with necrotizing pneumococcal pneumonia. We conducted a retrospective study of 15 children with a diagnosis of necrotizing pneumococcal pneumonia at National Taiwan University Hospital to explore its association with pulmonary gangrene, based on evidence from chest computed tomography, serial chest radiographic patterns, and pathologic results. *S. pneumoniae* serotype 14 was the prevalent pneumococcal serotype. Overall, 63.6% of isolates were not susceptible to penicillin. One child with pneumonia caused by *S. pneumoniae* serotype 3 complicated by hemolytic uremic syndrome had a rapidly fatal course. An autopsy in this patient documented lung necrosis and pulmonary gangrene. Radiographic follow-up was performed during the clinical course in 9 patients, and showed no evidence of pulmonary gangrene. Four children had no radiographic follow-up. The relationship between pulmonary gangrene and necrotizing pneumonia was unclear in the remaining one. In conclusion, necrotizing pneumococcal pneumonia may be infrequently associated with pulmonary gangrene in children. **Pediatr Pulmonol.** 2006; 41:623–629. © 2006 Wiley-Liss, Inc.

**Key words:** *Streptococcus pneumoniae*; necrosis; thrombosis; pneumonia.

## INTRODUCTION

Severe pneumonia leading to necrosis, lung abscesses, or pneumatocele is generally considered a rare complication of pneumococcal infection. In the past, necrotizing pneumonia was primarily found in adults affected by alcoholism or heavy cigarette smoking, leading some experts to speculate that the mixed anaerobic infection plays a major role in necrotizing pneumococcal pneumonia.<sup>1,2</sup> However, since 1990, an increase in necrotizing pneumococcal pneumonia has been observed in children, especially in Taiwan, where pneumococcal vaccination is not widely implemented.<sup>3–7</sup> Necrotizing pneumonia caused by *Staphylococcus aureus* is highly associated with the presence of Paton-Valentine leukocidin, a cytotoxin-damaging leukocyte, and host tissues.<sup>8</sup> After group A *Streptococcus* infection, M protein, a virulence factor associated with tissue necrosis, contributes to intravascular thrombosis and rapid tissue destruction.<sup>9</sup> The mechanisms responsible for destructive lung injury in pneumococcal infection remain unclear.

Pulmonary gangrene, characterized by the sloughing of a large amount of lung tissue due to severe pneumonia, was reported to be the underlying process in adults with necrotizing pneumococcal pneumonia.<sup>10,11</sup> The diagnosis of pulmonary gangrene is mainly made by serial radiographic evaluation and pathological examination.<sup>11,12</sup>

We retrospectively reviewed 15 children with necrotizing pneumonia caused by *S. pneumoniae*, to analyze the association with pulmonary gangrene via clinical course, chest computed tomography (CT), and a series of radiographic findings. This work was based on the

<sup>1</sup>Section of Infection, Department of Medicine, Wan-Fang Hospital, Taipei Medical University, Taipei, Taiwan.

<sup>2</sup>Department of Pathology, National Taiwan University Hospital, Taipei, Taiwan.

<sup>3</sup>Department of Pediatrics, National Taiwan University Hospital, Taipei, Taiwan.

<sup>4</sup>Department of Internal Medicine, National Taiwan University Hospital, Taipei, Taiwan.

<sup>5</sup>Department of Laboratory Medicine, National Taiwan University Hospital, Taipei, Taiwan.

\*Correspondence to: Dr. Li-Min Huang, Department of Pediatrics, National Taiwan University Hospital, No. 7 Chung-Shan South Road, 100 Taipei, Taiwan.

Received 14 November 2005; Accepted 6 February 2006.

DOI 10.1002/ppul.20411

Published online 15 May 2006 in Wiley InterScience (www.interscience.wiley.com).

difference between necrotizing pneumonia (a pathology) and pulmonary gangrene (a pathophysiological mechanism). In addition, a previously undocumented pediatric condition of fatal pneumococcal infection complicated by necrotizing pneumonia with abscess formation, pulmonary gangrene secondary to vascular thrombosis, and hemolytic uremic syndrome is reported in detail.

## MATERIALS AND METHODS

### Patients

All 56 children under 15 years old with a diagnosis of pneumococcal pneumonia who were admitted to National Taiwan University Hospital (NTUH), a medical center with 2,000 beds in northern Taiwan, between May 1998–July 2003, were included. One child who died of pneumococcal pneumonia in another hospital and was sent to NTUH for autopsy in December 2004 was also studied.

### Diagnosis

The diagnosis of pneumococcal pneumonia was established according to clinical symptoms, a consolidation pattern on chest images, and positive blood culture, positive pleural fluid culture, or positive antigen detection in the pleural fluid using latex agglutination (Sanofi Diagnostics Pasteur, France). Chest radiographs were performed in each patient at admission, with follow-up radiographs every 3–7 days during hospitalization. If the patient was discharged, follow-up chest radiographs were performed at clinics. All patients except one received chest CT during hospitalization. Twelve patients received chest CT within 1 week of admission, and 2 patients received chest CT during the second week after admission. Chest images were independently reviewed by one radiologist and one chest specialist. Necrotizing pneumonia was defined as the presence of lucencies in the consolidation area on chest radiograph, or cavities with a background of liquefaction on CT of the chest. The diagnosis of pulmonary gangrene was based on characteristic chest CT, serial radiographic, or pathological findings.<sup>10–12</sup> Pulmonary gangrene was diagnosed based

on previously described radiographic findings, including a severely narrowed bronchus leading to the cavity, floating pulmonary fragments, pattern of a crescent sign, mass within the cavity, and loss of lung volume on the affected lobe at the postpulmonary-gangrene stage.<sup>10–12</sup> Patients who only had empyema were excluded from the study. Postmortem tissue samples were examined by light microscopy.

### Bacterial Isolates, Antimicrobial Susceptibility Testing, and Serotyping

The only *S. pneumoniae* isolate from the autopsy case was from blood. Isolates in 10 of the other 14 patients were from blood or pleural effusion (2 isolates from the blood, 5 isolates from pleural effusion, and 3 isolates from both blood and pleural effusion). Minimal inhibitory concentrations (MICs) of penicillin were determined by the E-test (AB Biodisk, Solna, Sweden). Criteria used to define susceptibility or nonsusceptibility followed the guidelines of the Clinical and Laboratory Standards Institute (CLSI, formerly the National Committee for Clinical Laboratory Standards; meningitis criteria).<sup>13</sup> Isolates were tested in duplicate, using a slide agglutination assay with capsular type-specific antisera to determine the serotype of each strain (Statens Serum Institut, Copenhagen, Denmark).<sup>14</sup>

## RESULTS

Fifty-six patients in NTUH with pneumococcal pneumonia were identified between May 1998–July 2003. The incidence of necrotizing pneumonia among children with pneumococcal pneumonia was 25% (14/56). The characteristics of a total of 15 patients with necrotizing pneumococcal pneumonia were analyzed (Table 1). The mean age was 49 months (median, 49 months; range, 9–85 months). The female-to-male ratio was 6.5 to 1. All patients were previously healthy, without underlying disease. Fever was noted for a median duration of 4 days prior to admission; the median duration from admission to the finding of cavitory lesions was 6 days; the median duration from admission to defervescence was 9 days; the median length of stay in hospital was 18 days. The clinical

**TABLE 1—Clinical Characteristics in 15 Patients With Necrotizing Pneumococcal Pneumonia**

Characteristics	Median (range) or number (%)
Age (months)	49 (9–85)
Gender: female, male	13 (86.7), 2 (13.3)
Fever days prior to admission (equivalent to duration from beginning of symptoms to initiation of antibiotic therapy)	4.0 (2–11)
Duration from admission to finding of cavitory lesions (days)	6 (1–12)
Duration from admission to defervescence (days)	9 (4–30)
Length of stay in hospital (days)	18 (5–40)

course was complicated by empyema in 14 patients, and chest tube insertion was performed in 14 patients (93.3%). Eight patients (53.3%) underwent video-assisted thoracoscopic surgery (VATS) for decortication. One child died due to the complication of pneumococcal infection. Eleven bacterial isolates were assayed for antibiotic sensitivity, using the E-test. Among them, 36.4% of the isolates were susceptible (MIC,  $\leq 0.06$   $\mu\text{g/ml}$ ), 45.4% of the isolates were intermediate (MIC, 0.1–1  $\mu\text{g/ml}$ ), and 18.2% of the isolates were resistant to penicillin (penicillin MIC,  $\geq 2$   $\mu\text{g/ml}$ ) (Table 2). Ten isolates were available for serotyping. Serotype 14 was found in 50% of patients, serotype 3 in 30%, and serotype 6A and 18C were each found in 10% of patients (Table 2). Except for *S. pneumoniae*, no other concomitant pathogens, including anaerobic bacteria, were found in these patients. Antibiotic treatment included parenteral  $\beta$ -lactams such as high-dose penicillin (400,000 U/kg/day), cefotaxime sodium, ceftriaxone sodium, or amoxicillin-clavulanic acid or glycopeptide (Vancomycin) (Table 2).

Cavitary lesions commonly appeared in the right upper lobe (6/15, 40%) of the lungs. On the background of consolidation with an air bronchogram, multifocal cavitations without a large area of liquefaction were noted in 13 patients (patients 1–13, Table 2). Four children had no radiographic follow-up (patients 1–4). During follow-up in patients 5–13, chest images showed complete resolution or only minimal residual fibrotic change over the previous area of consolidation (Table 2). Most patients had radiographic recovery within 1–3 months. Radiographic loss of lung volume was described as a sign of pulmonary gangrene in adults.<sup>11</sup> However, in the youngest patients who have potential postnatal lung growth, the sequelae of pulmonary gangrene in children can be minimal. Gangrenous pneumonia was not likely in these 9 patients (patients 5–13), due to good radiographic resolution without lung-volume reduction, based on serial radiographic follow-up. In patient 14, however, severe massive necrosis was noted on chest CT at admission. She was treated with antibiotics and VATS decortication. Although there were no typical cavitary lesions suggestive of pulmonary gangrene on chest radiograph, cicatrizing atelectasis of the right upper lobe was found on follow-up radiograph 6 months later (Table 2). Thus, the relationship between pulmonary gangrene and necrotizing pneumonia remained unclear in this patient.

### Report of Patient 15 (Autopsy Case)

A previously healthy 5-year-old Taiwanese girl was admitted 3 days after the onset of fever and cough. A chest radiograph showed consolidation of the right middle and lower lung, accompanied by empyema. Blood tests showed: leukocytes, 12,000/ $\text{mm}^3$  (normal value, 5,500–15,500); hemoglobin, 12.3 g/dl (normal value,

11.5–15.5); platelets, 116,000/ $\text{mm}^3$  (normal value, 150,000–400,000); and C-reactive protein (CRP), 42.9 mg/dl (normal value,  $<0.35$ ). Prothrombin time was 20.7 sec (normal value, 11–15 sec), and partial thromboplastin time was 45 sec (normal value, 25–35 sec). Under the impression of severe sepsis, Vancomycin (45 mg/kg daily) and cefotaxime sodium (150 mg/kg daily) were given on day 1. On day 2, a chest tube was inserted due to dyspnea. The pleural fluid was bloody, and analysis revealed 333/ $\text{mm}^3$  leukocytes, with 25% neutrophils and 75% lymphocytes. Protein was 3.6 g/dl, glucose was 11 mg/dl, and lactate dehydrogenase was 6,030 IU/ml. Blood culture yielded *Streptococcus pneumoniae* serotype 3. The MIC of penicillin was 0.064  $\mu\text{g/ml}$ . On day 3 of hospitalization, she developed oligouria. Hemoglobin fell to 5.9 mg/dl, platelets fell to 4,000/ $\text{mm}^3$ , and creatinine rose from 1.1 to 3.3  $\mu\text{mol/l}$  (normal value, 0.3–0.7). Fibrinogen was 243.2 mg/dl (normal value, 200–400). Analysis of biochemical hepatitis markers showed: aspartate aminotransferase, 485 units/l (normal value, 15–55); alanine aminotransferase, 101 units/l (normal value, 5–45); total bilirubin, 3.3 mg/dl (normal value, 0.2–1); and direct bilirubin, 1.1 mg/dl (normal value, 0–0.2). Urinalysis revealed proteinuria, positive occult blood, and 16–30 red blood cells per high-power field. Fresh-frozen plasma, platelets, and unwashed packed red blood cells were transfused due to symptoms of epistaxis and tarry stool. On hospital day 5, respiratory failure developed, and she was intubated with ventilator support. She died due to refractory shock and pulmonary edema on hospital day 5. An autopsy was performed within 12 hr after death. Gross inspection revealed that the middle lobe of the right lung was emphysematous, necrotic, and gangrenous. The gangrenous area showed large regions of infarction and necrosis (Fig. 1A). Intravascular thrombi were evident in the pulmonary artery within the infarcted region in the middle lobe of the right lung (Fig. 1B). Although pulmonary hypertension and right heart failure could have occurred secondary to pulmonary artery occlusion,<sup>15</sup> we found no evidence of pulmonary hypertension, such as medial hypertrophy or right ventricular hypertrophy, in the postmortem findings. The lower lobe of the right lung was consolidated. Microscopically, it showed diffuse neutrophilic infiltration within the alveolar spaces, with occasional disruption of the alveolar septum, which was demonstrated by reticular stain (Fig. 2A,B). The pathological finding of necrotizing pneumonia in the lower lobe of the right lung was not related to infarction. Histologically, both kidneys showed frequent fragmented red cells, fibrinous thrombi in the glomerular capillary lumen, and occasional extension to the afferent arterioles (Fig. 3). These findings met the criteria for a diagnosis of hemolytic uremic syndrome. No similar thrombus was seen in other organs.

**TABLE 2—Radiographic, Microbiologic Data and Antibiotic Therapy in 15 Patients With Necrotizing Pneumococcal Pneumonia**

Case no.	Location of cavitation <sup>1</sup>	Radiographic finding	Radiographic outcome (days after admission)	Serotype/penicillin MIC ( $\mu\text{g/ml}$ )	Antibiotic therapy <sup>5</sup> route, regimen, dose (mg/kg/day), and duration (days)
1	LLL	Necrosis, cavitation	No follow-up	14/0.38	1. i.v., amoxicillin/clavulanic acid, 100, 2
2 <sup>2</sup>	LLL	Necrosis, cavitation	No follow-up	ND/—	2. i.v., cefotaxime, 150, 36 1. i.v., ampicillin/sulbactam, 100, 2 2. i.v., vancomycin, 40, 31 i.v., ceftriaxone, 100, 31
3	LLL, LUL	Necrosis, cavitation	No follow-up	14/0.5	1. i.v., cefotaxime, 150, 16
4	RUL	Necrosis, cavitation, abscess formation	Cyst formation (55), no follow-up since then	14/0.094	1. i.v., vancomycin, 40, 22
5	RUL, RML	Necrosis, cavitation	Complete resolution (70)	6A/3	1. i.v., vancomycin, 40, 14 2. i.v., teicoplanin, 10, 13
6 <sup>2</sup>	RUL, RLL	Necrosis, cavitation	Minimal fibrotic infiltration (61)	ND/—	1. i.v., vancomycin, 40, 30 i.v., ceftriaxone, 100, 30
7 <sup>2</sup>	RLL	Necrosis, cavitation	Minimal fibrotic infiltration (20)	ND/—	1. i.v., amoxicillin/clavulanic acid, 100, 8 2. i.v., vancomycin, 40, 11 i.v., cefotaxime, 100, 11
8 <sup>2</sup>	LLL	Necrosis, cavitation, abscess formation	Complete resolution (82)	ND/—	1. i.v., amoxicillin/clavulanic acid, 100, 4 2. i.v., vancomycin, 40, 28 i.v., cefotaxime, 100, 28
9	LLL	Necrosis, cavitation	Minimal fibrotic infiltration (21)	ND/2	1. i.v., vancomycin, 40, 6 i.v., cefotaxime, 100, 6
10	RML, RLL	Necrosis, cavitation, abscess formation	Mild peribronchial thickening (158)	3/<0.06	2. i.v., penicillin, 400,000 U, 12 1. i.v., penicillin, 400,000 U, 2 2. i.v., cefotaxime, 100, 4
11	RUL	Necrosis, cavitation, pneumatocele	Minimal fibrotic infiltration (25)	14/1	3. i.v., ampicillin, 150, 10 4. Oral, amoxicillin, 40, 7 1. i.v., cefotaxime, 200, 12 2. i.v., vancomycin, 40, 6
12	RUL	Necrosis, cavitation	Minimal fibrotic infiltration (67)	3/<0.06	1. i.v., cefotaxime, 200, 15 2. Oral, amoxicillin, 50, 7 3. Oral, amoxicillin/clavulanic acid, 40, 10
13	RLL	Pneumothorax, necrosis, cavitation, pneumatocele	Minimal fibrotic infiltration (22)	18C/<0.06	1. i.v., cefotaxime, 150, 12
14	RUL	Necrosis, cavitation	Cicatrizing atelectasis of RUL (186)	14/0.25	1. i.v., cefotaxime, 150, 14
15 <sup>3</sup>	RML, RLL	Necrosis, cavitation <sup>4</sup>	Died	3/0.064	2. i.v., vancomycin, 40, 2 1. i.v., vancomycin, 45, 5 i.v., cefotaxime, 150, 5

<sup>1</sup>LLL, left lower lobe; LUL, left upper lobe; ND, not done; RLL, right lower lobe; RML, right middle lobe; RUL, right upper lobe; i.v., intravenous.

<sup>2</sup>Patients were diagnosed by positive antigen test.

<sup>3</sup>Only chest radiographs were available for patients.

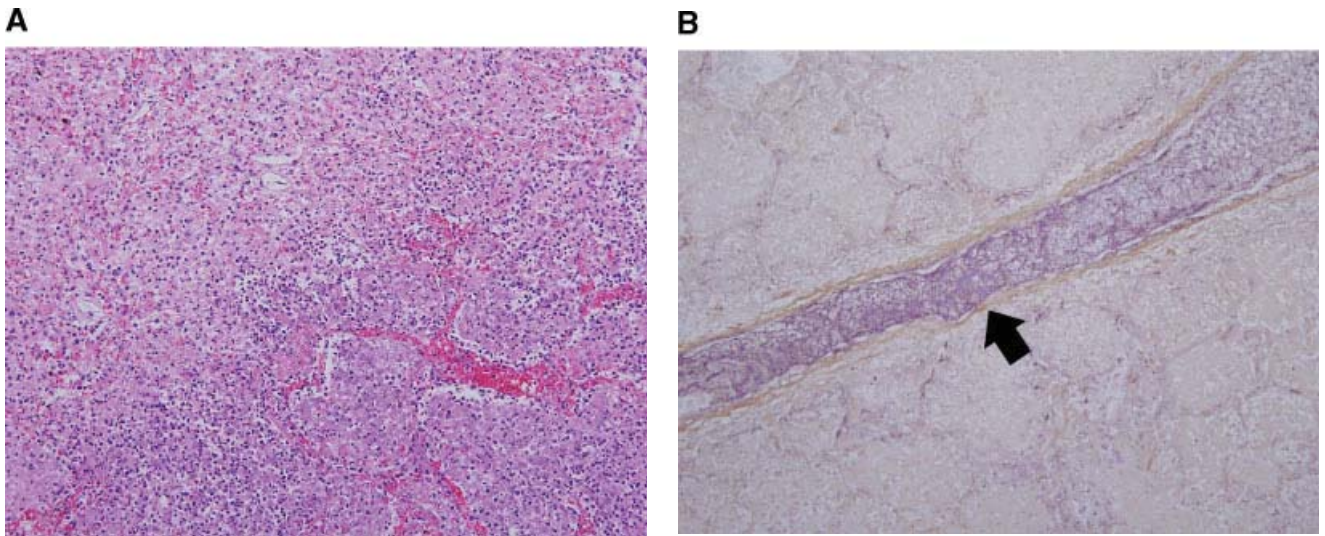
<sup>4</sup>Findings were noted by postmortem examination. There were no findings of cavitation on chest radiographs.

<sup>5</sup>1–3 indicate sequences of antibiotic regimen in each patient.

## DISCUSSION

A review of the literature reveals a paucity of data about cavitation in pediatric pneumococcal pneumonia.

Serotype 3 has often been associated with pulmonary suppuration and necrosis in adults, owing to its large amount of capsular polysaccharide antigen and its ability to resist phagocytosis.<sup>1,10</sup> A strain of serotype 14 with a



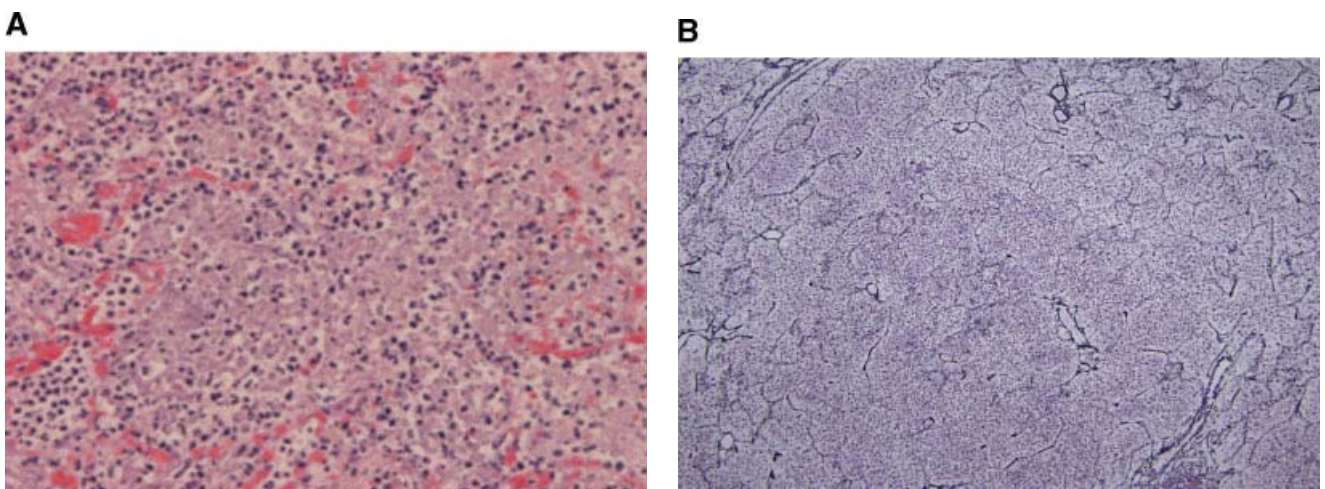
**Fig. 1. A:** Extensive inflammation and necrosis in right lower field indicates gangrene change (hematoxylin-eosin stain,  $\times 200$ ). **B:** Fibrinous thrombus (arrow) was found in large vessel within infarcted area. Fibrin content was confirmed by phosphotungstic acid hematoxylin (PTAH) stain (PTAH stain,  $\times 200$ ).

penicillin MIC of 4  $\mu\text{g/ml}$  was reported as the cause of necrotizing pneumonia in a child.<sup>3</sup> Pulmonary gangrene secondary to vascular thrombosis is thought to be involved in the tissue necrosis following pneumococcal infection, but this condition has never been documented in children.<sup>3,11</sup>

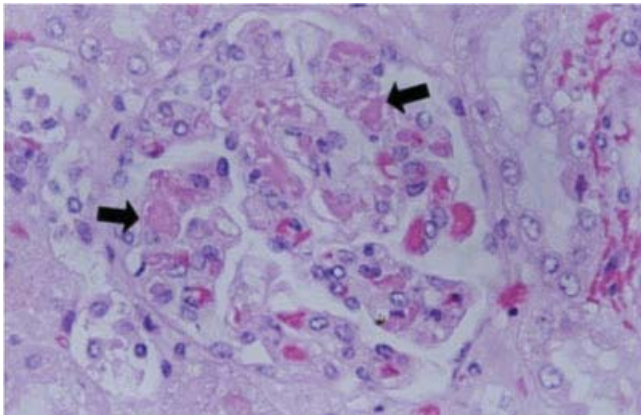
This is the first report to document necrotizing pneumococcal pneumonia associated with pulmonary gangrene in a child. Pulmonary gangrene is a life-threatening complication of severe pulmonary infection. It is characterized by pulmonary infarction of an entire segment or lobe due to simultaneous thrombosis of the dural arterial supply of the lung, pulmonary, and bronchial circulation.<sup>11</sup> Such extensive infarction is different from

thromboembolic disease, in which only the pulmonary artery is occluded, and the infarction is located peripherally. Massive necrotic tissue, including the thrombotic large vessels, results in difficulty in expectoration, which further complicates the disease. Clinically, necrotizing pneumonia or lung abscesses develop in the late phase of the disease. Distinguishing pulmonary gangrene from necrotizing pneumonia and lung abscesses becomes important in the early stage of the disease, when physicians must decide whether to perform surgical drainage in patients who are unresponsive to medical care.<sup>11</sup>

In this study, various serotypes were associated with necrotizing pneumonia in children. Serotype 14 was the



**Fig. 2. A:** Necrotizing pneumonia was characterized by diffuse neutrophilic infiltration and septal destruction (hematoxylin-eosin stain,  $\times 10$ ). **B:** Destruction of alveolar septa is evident on reticular staining (reticular stain,  $\times 100$ ).



**Fig. 3.** Fibrinous microthrombi (arrow) impacted in capillary lumen of glomerulus of kidney. Fragmented red cells were also noted (hematoxylin-eosin stain,  $\times 20$ ).

most prevalent serotype in this study, which is different from findings in adults.<sup>1</sup> In addition, these pediatric patients consisted predominantly of healthy female children, in contrast to previous reports in which patients consisted mainly of adult males with an underlying comorbid condition.<sup>1,2</sup> This observation may suggest that the pathogenesis of necrotizing pneumococcal pneumonia in children is different from that in adults. This study was limited by its evaluation of the relationship between necrotizing pneumonia and pulmonary gangrene using only radiographic images in the 14 survivors. It was not feasible to collect pathological specimens from these patients. In patient 15, necrotizing pneumonia related to pulmonary gangrene was not diagnosed radiographically but on pathologic examination at autopsy. A possible explanation for the lack of radiographic findings suggestive of this relationship is that additional time may be required from the onset of tissue liquefaction until the loss of tissue integrity and cavitation become apparent radiographically. The rapidly fatal course in this patient may not have allowed sufficient time for such radiographic findings to become manifest prior to death. Interpretation of serial radiographic follow-up images in patients 5–13 led to the conclusion that typical findings of pulmonary gangrene or radiographic loss of lung volume were not present in these 9 patients. Instead, the lesions gradually resolved or recovered completely without sequelae. These radiographic findings might suggest that pulmonary gangrene was not part of the underlying pathophysiological process in these 9 cases. The destructive injury to the lung parenchyma was possibly the consequence of severe inflammation, or of an unknown virulence factor secreted by the pneumococci.

Another important feature in the autopsy case of this report was the occurrence of thrombotic events in both the lung and kidney after *S. pneumoniae* infection, which was

not due to disseminated intravascular coagulopathy. Pneumococcus-induced hemolytic uremic syndrome is a rare disease which has high morbidity and mortality.<sup>16</sup> Neuraminidase release from *S. pneumoniae* was postulated to expose crypted Thomsen-Friedenreich antigen from red blood cells and endothelial cells, and to contribute to thrombotic microangiopathy in the kidney.<sup>16</sup> On the other hand, pneumococcal cell walls were demonstrated to have the ability to activate the procoagulant cascade, leading to intravascular fibrin formation and deposition.<sup>17,18</sup> Whether the extensive pulmonary vascular thrombosis is attributable to a large bacterial load, or to the increased activity of neuraminidase that damages pulmonary endothelial cells, is worthy of investigation.

In conclusion, *S. pneumoniae* can cause necrotizing pneumonia in children, which may result from vascular thrombosis and pulmonary gangrene in a low percentage of children. Further studies to determine the mechanism of tissue necrosis caused by *S. pneumoniae* are needed.

## REFERENCES

1. Yango BG, Deresinski SC. Necrotizing or cavitating pneumonia due to *Streptococcus pneumoniae*: report of four cases and review of the literature. *Medicine (Baltimore)* 1980;59:449–457.
2. Leatherman JW, Iber C, Davies SF. Cavitation in bacteremic pneumococcal pneumonia. Causal role of mixed infection with anaerobic bacteria. *Am Rev Respir Dis* 1984;129:317–321.
3. Kerem E, Bar Ziv Y, Rudenski B, Katz S, Kleid D, Branski D. Bacteremic necrotizing pneumococcal pneumonia in children. *Am J Respir Crit Care Med* 1994;149:242–244.
4. McCarthy VP, Patamasucon P, Gaines T, Lucas MA. Necrotizing pneumococcal pneumonia in childhood. *Pediatr Pulmonol* 1999;28:217–221.
5. Tan TQ, Mason EO Jr, Wald ER, Barson WJ, Schutze GE, Bradley JS, Givner LB, Yogev R, Kim KS, Kaplan SL. Clinical characteristics of children with complicated pneumonia caused by *Streptococcus pneumoniae*. *Pediatrics* 2002;110:1–6.
6. Chen KC, Su YT, Lin WL, Chiu KC, Niu CK. Clinical analysis of necrotizing pneumonia in children: three-year experience in a single medical center. *Acta Paediatr Taiwan* 2003;44:343–348.
7. Hsieh YC, Hsueh PR, Lu CY, Lee PI, Lee CY, Huang LM. Clinical manifestations and molecular epidemiology of necrotizing pneumonia and empyema caused by *Streptococcus pneumoniae* in children in Taiwan. *Clin Infect Dis* 2004;38:830–835.
8. Gillet Y, Issartel B, Vanhems P, Fournet JC, Lina G, Bes M, Vandenesch F, Piemont Y, Brousse N, Floret D, Etienne J. Association between *Staphylococcus aureus* strains carrying gene for Panton-Valentine leukocidin and highly lethal necrotising pneumonia in young immunocompetent patients. *Lancet* 2002;359:753–759.
9. Bryant AE. Biology and pathogenesis of thrombosis and procoagulant activity in invasive infections caused by group A *Streptococci* and *Clostridium perfringens*. *Clin Microbiol Rev* 2003;16:451–462.
10. Hammond JM, Lyddell C, Potgieter PD, Odell J. Severe pneumococcal pneumonia complicated by massive pulmonary gangrene. *Chest* 1993;104:1610–1612.
11. Penner C, Maycher B, Long R. Pulmonary gangrene. A complication of bacterial pneumonia. *Chest* 1994;105:567–573.

12. Reich JM. Pulmonary gangrene and the air crescent sign. *Thorax* 1993;48:70–74.
13. Clinical and Laboratory Standards Institute. Performance standards for antimicrobial susceptibility testing; 15th informational supplement. Document M100-S15. Wayne, PA: Clinical and Laboratory Standards Institute; 2005.
14. Facklam RR, Washington JA II. *Streptococcus* and related catalase-negative Gram positive cocci. In: Balows A, Hausler WJ, Hermann RL, Isenberg HD, Shadomy HJ, editors. *Manual of clinical microbiology*. 5th ed. Washington, DC: American Society for Microbiology; 1991. pp 38–257.
15. Fedullo PF, Auger WR, Kerr KM, Rubin LJ. Chronic thromboembolic pulmonary hypertension. *N Engl J Med* 2001;345:1465–1472.
16. Brandt J, Wong C, Mihm S, Roberts J, Smith J, Brewer E, Thiagarajan R, Warady B. Invasive pneumococcal disease and hemolytic uremic syndrome. *Pediatrics* 2002;110:371–376.
17. Tuomanen EI, Austrian R, Masure HR. Pathogenesis of pneumococcal infection. *N Engl J Med* 1995;332:1280–1284.
18. Geelen S, Bhattacharyya C, Tuomanen E. Induction of procoagulant activity on human endothelial cells by *Streptococcus pneumoniae*. *Infect Immun* 1992;60:4179–4183.