



Original Contribution

## D-Dimer in patients with suspected acute mesenteric ischemia

Yu-Hui Chiu MD<sup>a,b,c</sup>, Ming-Kun Huang MD<sup>a,c</sup>, Chorng-Kuang How MD<sup>a,c,d,\*</sup>,  
Teh-Fu Hsu MD<sup>a,c</sup>, Jen-Dar Chen MD<sup>c,e</sup>, Chii-Hwa Chern MD<sup>a,c</sup>,  
David Hung-Tsang Yen MD, PhD<sup>a,c</sup>, Chun-I Huang MD<sup>a,c</sup>

<sup>a</sup>Emergency Department, Taipei Veterans General Hospital, Taipei 112, Taiwan

<sup>b</sup>Emergency Department, Taipei Medical University-Wan Fang Hospital, Taipei 116, Taiwan

<sup>c</sup>Department of Emergency Medicine, National Yang-Ming University School of Medicine, Taipei 112, Taiwan

<sup>d</sup>Institute of Clinical Medicine, National Yang-Ming University School of Medicine, Taipei 112, Taiwan

<sup>e</sup>Radiology Department, Taipei Veterans General Hospital, Taipei 112, Taiwan

Received 29 May 2009; accepted 29 June 2009

### Abstract

**Objectives:** The aims of this study were to assess the diagnostic value of D-dimer in patients with suspected acute mesenteric ischemia (AMI) and to evaluate the correlation between D-dimer levels and the severity of bowel necrosis.

**Methods:** A prospective, noninterventional study of 67 patients with clinical suspicion of AMI was performed. Measurement of D-dimer levels was performed using a latex turbidimetric method.

**Results:** Acute mesenteric ischemia was diagnosed in 23 patients (34.3%) and non-AMI in 44 patients (65.7%). Median D-dimer levels on admission were 6.24  $\mu\text{g}$  fibrinogen equivalent units (FEU)/mL (range, 0.96–53.48  $\mu\text{g}$  FEU/mL) in patients with AMI and 3.45  $\mu\text{g}$  FEU/mL (range, 0.50–44.69  $\mu\text{g}$  FEU/mL) in non-AMI patients ( $P = .064$ ). D-Dimer had poor discriminative value to differentiate the presence from the absence of AMI with an area under the receiver operating characteristic curve of 0.64 (95% confidence interval, 0.50–0.78). A serum D-dimer cutoff value of 1.0  $\mu\text{g}$  FEU/mL had a sensitivity of 96%, a specificity of 18%, a positive likelihood ratio of 1.17, and a negative likelihood ratio of 0.24. Among patients with AMI verified at operation, 8 had resectable bowel necrosis and 9 had unresectable bowel necrosis. There was no difference in serum D-dimer levels between resectable and unresectable bowel necrosis ( $P = .665$ ).

**Conclusions:** Detection of serum D-dimer could not help to differentiate patient with AMI from those with non-AMI. We did not find a correlation between serum D-dimer levels and the severity of AMI. However, measurement of D-dimer levels can be of value for a small decrease in the likelihood of AMI, when the result is low.

© 2009 Elsevier Inc. All rights reserved.

## 1. Introduction

Acute mesenteric ischemia (AMI) is a devastating vascular emergency with overall mortality of 60% to 80% [1–3]. Prompt recognition and early revascularization would

\* Corresponding author. Emergency Department, Taipei Veterans General Hospital, Taipei 112, Taiwan. Tel.: +886 2 2857377; fax: +886 2 28738013.

E-mail address: ckhov@vghtpe.gov.tw (C.-K. How).

be a prerequisite for survival. The high mortality rate of AMI is mainly due to delay in diagnosis. Various clinical and laboratory parameters such as white cell count, serum lactate concentration, or amylase activity have been assayed for this purpose, but no clinically useful results have been obtained [4-6].

The fibrinolytic marker D-dimer has been widely used in emergency department (ED) for assessing various clinical conditions. Three recent clinical studies showed that D-dimer could be useful in identifying patients with acute thromboembolic occlusion of the superior mesenteric artery (SMA) and have a good negative predictive value [6-8]. In rats undergoing ligation of SMA, serum D-dimer levels increase with the duration of the intestinal ischemia period [9]. On the other hand, in another controlled rat model, there was no difference of serum D-dimer levels between ligation and simply manipulation of SMA [10]. Due to small sample sizes, limitation in arterial occlusion, and inconclusive results in previous reports, further studies are needed.

The aims of the present study are to assess the diagnostic value of D-dimer in ED patients with suspected AMI and to evaluate the correlation between D-dimer levels and the severity and extension of bowel necrosis.

## 2. Materials and methods

This prospective, noninterventional study was conducted in the ED of Taipei Veterans General Hospital, a tertiary care medical center located in Taipei City, Taiwan, with 2700 admission beds and an ED annual census of approximately 80 000. The institutional review board approved the study, and patients or their next of kin provided written informed consent before enrollment. All consecutive patients 18 years or older who presented to our ED with acute abdominal pain and clinical suspicion of AMI from October 2007 to February 2009 were prospectively enrolled. Patients were excluded if they were pregnant, presented with death at arrival post-cardiopulmonary resuscitation state, or underwent anticoagulation that could decrease D-dimer levels significantly [11,12].

After enrollment, the following items were recorded for each patient: age, sex, medical history, and routine blood test values. All patients were examined with a 40-slice multidetector computed tomography (CT; Philips, Cleveland, OH; 40 × 0.625-mm collimation, 500-millisecond rotation, 120 kV). Before CT, blood samples were taken for the investigation of D-dimer level, as well as amylase and lactate. For patients without renal insufficiency or contrast hypersensitivity, biphasic CT with mesenteric CT angiography was performed as described in previous literature [13]. Computed tomographic scans were evaluated for evidence of pneumatosis intestinalis, superior mesenteric or portal venous gas, bowel-wall thickening, focal lack of bowel-wall enhancement, and mesenteric arterial or venous

thrombosis. For patients with a contraindication to the intravenous contrast agent, nonenhanced CT was done to search any indirect signs of AMI and rule out other etiologies of acute abdomen. All patients were treated according to the usual practice of the ED, without interference by the research team. According to the radiologic, surgical, and pathologic results, the diagnosis of each patient was retrospectively classified as either AMI or non-AMI.

Measurement of D-dimer levels was performed using a Dade Behring Advanced D-dimer assay (Siemens Diagnostics, Newark, De) with the aid of an automated chemical analysis system (model CA-7000; Sysmex, Kobe, Japan). This test uses a latex-bound monoclonal antibody that is specific to D-dimer. The reaction is followed at an assay temperature of 37°C via the increase in turbidity at a wavelength ranging from 575 to 800 nm. The result is available in 7 to 10 minutes. The lower cutoff value for the exclusion of venous thromboembolism (deep vein thrombosis or pulmonary embolism), which is the main use of the test in our hospital, is 1.0 µg FEU/mL. The test has a lower detectable limit of 0.43 µg FEU/mL.

Descriptive results were reported as mean ± SD or median (range) when appropriate. Variables were evaluated for an association with the diagnosis with the use of Pearson  $\chi^2$  test (or the Fisher exact test when appropriate) for categorical data and Mann-Whitney *U* test for numerical data. The groups were compared with the use of the Mann-Whitney *U* test for numerical data and the Pearson  $\chi^2$  test for categorical data. Receiver operating characteristic (ROC) curve was applied to determine the most suitable diagnostic value for D-dimer levels. All statistical analyses were completed with SPSS 13.0 version software SPSS (Chicago, Ill), and a 2-tailed *P* value less than .05 was considered significant.

## 3. Results

Sixty-seven patients with clinical suspicion of AMI met our study criteria and were enrolled for further analysis. The mean (SD) age of the patients was 75.5 (13.5) years (range, 30-94 years). There were 48 men (71.6%) and 19 women (28.4%). Acute mesenteric ischemia was diagnosed in 23 patients (34.3%) and non-AMI in 44 patients (65.7%). The clinical characteristics of the overall study group were shown in Table 1. The mortality rate was 57% in patients with AMI and 23% in patient with non-AMI (*P* = .013). Among patients with AMI, 17 patients had surgery (8 bowel resection, 3 revascularization, and 9 open and closed laparotomy because of diffuse bowel gangrene), 3 selected patients with SMA occlusion on CT angiography and no peritoneal signs underwent emergent angiography and intra-arterial thrombolytic therapy (1 survival and 2 dead subsequently), and 3 patients with mesenteric venous

**Table 1** Clinical and biological data at admission and patient outcomes

	All patients (n = 67)	Patients with AMI (n = 23)	Patients with non-AMI (n = 44)	<i>P</i> <sup>a</sup>
Age (y)	75.5 ± 13.5	74.2 ± 13.6	76.2 ± 13.5	.234
Sex (M/F)	48/19	17/6	31/13	.990
Mortality rate, n (%)	23 (34)	13 (57)	10 (23)	.013
Leukocyte count (×10 <sup>9</sup> cells/L)	13.9 ± 7.2	15.2 ± 6.7	13.1 ± 7.4	.200
Amylase (U/L), median (range)	119 (18-2850)	215 (38-875)	109 (18-2850)	.078
Lactate (mg/dL), median (range)	32.1 (5.6-294.5)	32.1 (5.6-294.5)	33.0 (6.8-126.6)	.884
D-Dimer (μg FEU/mL), median (range)	3.51 (0.50-53.48)	6.24 (0.96-53.48)	3.45 (0.50-44.69)	.064

Values are presented as mean ± SD, unless otherwise indicated.

<sup>a</sup> For comparison of patients with and those without AMI.

thrombosis were treated with anticoagulation alone. The non-AMI was caused by the following: intestinal obstruction (n = 13, including 7 strangulation), infectious enterocolitis (n = 10), intra-abdominal infection (n = 7), ischemic colitis (n = 4), hollow organ perforation (n = 4), paralytic ileus (n = 3), and inflammatory bowel disease (n = 3). The etiologic factors of the AMI and non-AMI groups were summarized in Table 2.

There were no missing or indeterminate values for D-dimer. Median D-dimer levels on admission were 6.24 μg FEU/mL (range, 0.96-53.48 μg FEU/mL) in patients with AMI and 3.45 μg FEU/mL (range, 0.50-44.69 μg FEU/mL) in non-AMI patients. However, there were no statistically significant differences between these 2 groups regarding the D-dimer levels (*P* = .064). The capacity of serum D-dimer to differentiate the presence from the absence of AMI was assessed with an ROC curve analysis (Fig. 1). The area under the ROC curves when serum D-dimer was used in differentiating between AMI and non-AMI was 0.64 (95% confidence interval, 0.50-0.78). A serum D-dimer cutoff value of 1.0 μg FEU/mL had a sensitivity of 96%, a specificity of 18%, a positive likelihood ratio of 1.17, and a negative likelihood ratio of 0.24.

We further evaluated the relationship between serum D-dimer levels and the severity of AMI. Among patients with

AMI verified at operation, 8 had resectable bowel necrosis and 9 had unresectable bowel necrosis due to diffuse bowel gangrene. The serum D-dimer levels according to disease severity are shown in Fig. 2. Box plots show that there was no difference in serum D-dimer levels between resectable and unresectable bowel necrosis (*P* = .665).

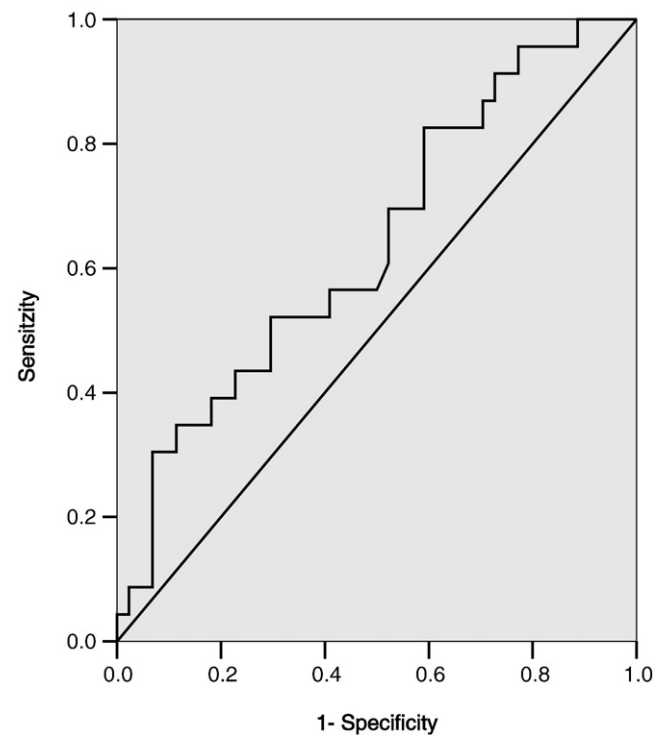
#### 4. Discussion

Mesenteric ischemia is a life-threatening vascular emergency that requires early diagnosis and intervention to adequately restore mesenteric blood flow and to prevent

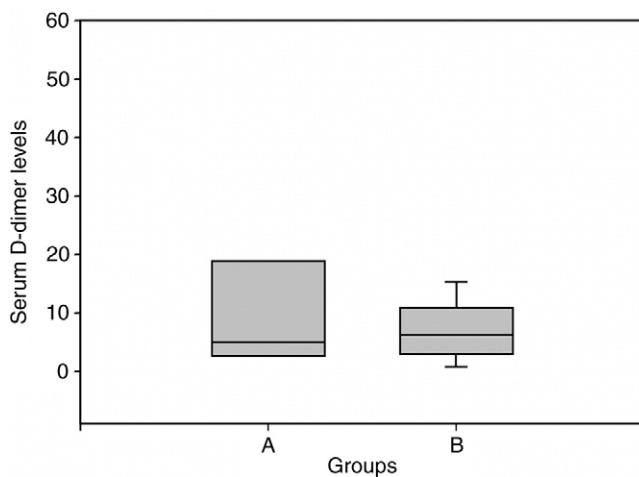
**Table 2** Etiologic factors

Patients with AMI (n = 23)	
Arterial embolus	12
Arterial thrombosis	5
Nonocclusive	3
Venous thrombosis	3
Patients with non-AMI (n = 44)	
Intestinal obstruction <sup>a</sup>	13
Infectious enterocolitis	10
Intra-abdominal infection	7
Ischemic colitis	4
Hollow organ perforation	4
Paralytic ileus	3
Inflammatory bowel disease	3

<sup>a</sup> Including 7 strangulations.



**Fig. 1** Receiver operating characteristic curve for various cutoff levels of serum D-dimer in differentiating between AMI and non-AMI. Area under the ROC curves was 0.64 (95% confidence interval, 0.50-0.78).



**Fig. 2** Serum D-dimer levels according to diagnosis. Group A (n = 8): resectable acute mesenteric ischemic; group B (n = 9): unresectable AMI. Box plots show that there was no difference in serum D-dimer levels between both groups ( $P = .665$ ).

bowel necrosis and patient death. Acute intestinal ischemia results in local intravascular coagulation and fibrin deposition. D-Dimer is the enzyme degradation product of fibrin. As a result, the levels of D-dimer might increase [14]. Our results do not support the use of serum D-dimer as a reliable diagnostic marker in patients with clinical suspicion of AMI. The area under the ROC curves when D-dimer was used to differentiate the presence from the absence of AMI reported in this study is poor. The increase in D-dimer concentration with AMI was consistent with previous reports [6,7,9]. However, D-dimer was also elevated in other surgical or nonsurgical acute abdominal conditions. It has been known that strangulated small bowel obstruction [7,15], incarcerated hernia [15], symptomatic abdominal aortic aneurysm [7,16], and pancreatitis [17] are associated with raised D-dimer levels. We also found that there was no correlation between serum D-dimer levels and the severity of AMI. There was no difference in serum D-dimer levels between resectable and unresectable bowel necrosis. Icoz et al [15] have reported that D-dimer is not predictive for resection in strangulated intestinal hernia.

D-Dimer assay has limited specificity because many conditions are associated with fibrin formation. The main advantage of D-dimer in the diagnosis of thromboembolic events is high negative predictive value [18]. D-Dimer may be used for the identification of atherosclerotic complications [9]. A normal level of D-dimer points out to the absence of a thromboembolic event in the mesenteric artery, thereby providing an important marker for differential diagnosis [6,7]. Our findings revealed that an elevated D-dimer level on admission had a high sensitivity for identifying patients with AMI, but it had a low specificity. A negative test for D-dimer showed a small decrease in the likelihood of AMI. The one-negative D-dimer results were  $0.96 \mu\text{g FEU/mL}$ , and the patient had unresectable AMI secondary to SMA occlusion.

Our study has several strengths. The study sample involved a diverse group of critically ill adults admitted to ED in various phases of AMI and non-AMI conditions. Not only arterial occlusion but also venous thrombosis and nonocclusive type of AMI were included in this study. This increases the generalizability of our findings. Our study was designed as a real-life study. We did not include controls without suspected AMI, only patients with a high pretest probability of AMI, covering the spectrum of patients that is likely to be encountered in the future use of this test.

Measuring of D-dimer levels was performed using 3 different types of assays: enzyme-linked immunosorbent assay (ELISA), immunoturbidimetric test, and latex agglutination assay. The D-dimer assay used in this study is a latex-enhanced turbidimetric test for the quantitative determination of D-dimers. D-Dimer tests using latex turbidimetric methods seem to have test characteristics comparable to those for ELISA methods [19]. Although ELISA is the criterion standard, the less cumbersome and comparatively quick immunoturbidimetric test is currently the best D-dimer assay for use in emergency medicine [18].

Our studies had several limitations. First, not all the diagnoses of AMI were verified at operation. Three cases of SMA occlusion established the diagnoses with angiography. Another 3 mesenteric venous thrombosis were diagnosed with CT scans. Computed tomography is more sensitive in diagnosing venous thrombus than other types of AMI and is the investigation of choice in suspected cases of mesenteric venous thrombosis [3]. There was no potential misclassification bias in our study. Second, no case of chronic mesenteric ischemia was included in this study. The role of D-dimer in such condition is unknown.

## 5. Conclusions

Our data demonstrated that detection of serum D-dimer could not help to differentiate patient with AMI from those with non-AMI. We did not find a correlation between serum D-dimer levels and the severity of AMI. However, measurement of D-dimer levels can be of value for a small decrease in the likelihood of AMI, when the result is low.

## References

- [1] Stoney RJ, Cunningham CG. Acute mesenteric ischemia. *Surgery* 1993;114:489-90.
- [2] Mamode N, Pickford I, Leiberman P. Failure to improve outcome in acute mesenteric ischemia: seven year review. *Eur J Surg* 1999;165: 203-8.
- [3] Oldenburg WA, Lau LL, Rodenberg TJ, et al. Acute mesenteric ischemia: a clinical review. *Arch Intern Med* 2004;164:1054-62.
- [4] Potts FEIV, Vukov LF. Utility of fever and leucocytosis in acute surgical abdomens in octogenarians and beyond. *J Gerontol A Biol Sci Med Sci* 1999;54:M55-8.

- [5] Lange H, Jackel R. Usefulness of plasma lactate concentration in the diagnosis of acute abdominal disease. *Eur J Surg* 1994;160: 381-4.
- [6] Acosta S, Bjorck M. Acute thrombo-embolic occlusion of the superior mesenteric artery: a prospective study in a well-defined population. *Eur J Vasc Endovasc Surg* 2003;26:179-83.
- [7] Acosta S, Nilsson TK, Bjorck M. Preliminary study of D-dimer as a possible marker of acute bowel ischaemia. *Br J Surg* 2001;88: 385-8.
- [8] Acosta S, Nilsson TK, Bjorck M. D-Dimer testing in patients with suspected acute thromboembolic occlusion of the superior mesenteric artery. *Br J Surg* 2004;91:991-4.
- [9] Altinyollar H, Boyabatli M, Berberoglu U. D-Dimer as a marker for early diagnosis of acute mesenteric ischemia. *Thromb Res* 2006;117: 463-7.
- [10] Kulacoglu H, Kocaerkek Z, Moran M, et al. Diagnostic value of blood D-dimer levels in acute mesenteric ischemia in the rat : an experimental study. *Asian J Surg* 2005;28:131-5.
- [11] Li-Saw-Hee FL, Blann AD, Lip GY. Effects of fixed low-dose warfarin, aspirin-warfarin combination therapy, and dose-adjusted warfarin on thrombogenesis in chronic atrial fibrillation. *Stroke* 2000; 31:828-33.
- [12] Counturaud F, Kearon C, Bates SM, et al. Decrease in sensitivity of D-dimer for acute venous thromboembolism after starting anticoagulant therapy. *Blood Coagul Fibrin* 2002;13:241-6.
- [13] Kirkpatrick ID, Kroeker MA, Greenberg HM. Biphasic CT with mesenteric CT angiography in the evaluation of acute mesenteric ischemia: initial experience. *Radiology* 2003;229:91-8.
- [14] Schoots IG, Levi M, Paulina Roossink EH, et al. Local intravascular coagulation and fibrin deposition on intestinal ischemia-reperfusion in rats. *Surgery* 2003;133:411-9.
- [15] Icoz G, Makay O, Sozbilen M, et al. Is D-dimer a predictor of strangulated intestinal hernia? *World J Surg* 2006;30:2165-9.
- [16] Adam DJ, Haggart PC, Ludlam CA, et al. Hemostatic markers before operation in patients with acutely symptomatic nonruptured and ruptured infrarenal abdominal aortic aneurysm. *J Vasc Surg* 2002;35: 661-5.
- [17] Salomone T, Tosi P, Palareti G, et al. Coagulative disorders in human acute pancreatitis: role for the D-dimer. *Pancreas* 2003;26:111-6.
- [18] Wakai A, Gleeson A, Winter D. Role of fibrin D-dimer testing in emergency medicine. *Emerg Med J* 2003;20:319-25.
- [19] Brown MD, Lau J, Nelson RD, et al. Turbidimetric D-dimer test in the diagnosis of pulmonary embolism: a meta-analysis. *Clin Chem* 2003; 49:1846-53.