

Eradication of *Helicobacter pylori* significantly reduced gastric damage in nonsteroidal anti-inflammatory drug-treated Mongolian gerbils

Chun-Chao Chang, Sheng-Hsuan Chen, Gi-Shih Lien, Horng-Yuan Lou, Ching-Ruey Hsieh, Chia-Lang Fang, Shiann Pan

Chun-Chao Chang, Sheng-Hsuan Chen, Gi-Shih Lien, Horng-Yuan Lou, Ching-Ruey Hsieh, Chia-Lang Fang, Shiann Pan, Division of Gastroenterology, Department of Internal Medicine, Taipei Medical University Hospital; Digestive Disease Research center, Taipei Medical University, Taipei, Taiwan, China

Supported by Taipei Medical University Research Foundation, TMU92-AE-B38 and Wu-Wu Tan Research Foundation

Correspondence to: Dr. Chun-Chao Chang, Division of Gastroenterology, Department of Internal Medicine, Taipei Medical University Hospital. No. 252, Wu-Hsing Street, Taipei, Taiwan, China. chunchao@tmu.edu.tw

Telephone: +886-2-27372181-3903 Fax: +886-2-27363051

Received: 2004-05-25 Accepted: 2004-06-25

Abstract

AIM: To examine the effect of eradication of *Helicobacter pylori* prior to usage of NSAIDs, by investigating gastric inflammatory activity, myeloperoxidase (MPO) activity, prostaglandin (PG) E₂ synthesis in *H pylori*-infected, and *H pylori*-eradicated gerbils followed by administration of indomethacin and rofecoxib.

METHODS: Six-week-old male gerbils were orally inoculated with *H pylori*. Seven weeks later, anti-*H pylori* triple therapy and vehicle were given to gerbils respectively and followed by oral indomethacin (2 mg/kg.d) or rofecoxib (10 mg/kg.d) for 2 wk. We examined the area of lesions, gastric inflammatory activity, PGE₂ synthesis and MPO activity in the stomach.

RESULTS: In indomethacin and rofecoxib-treated gerbils, the following results were obtained in *H pylori*-infected group vs *H pylori*-eradicated group respectively: hyperplasia area of the stomach (mm²): 82.4±9.2 vs 13.9±3.5 (*P*<0.05), 30.5±5.1 vs 1.3±0.6 (*P*<0.05); erosion and ulcer area (mm²): 14.4±4.9 vs 0.86±0.5 (*P*<0.05), 1.3±0.6 vs 0.4±0.3 (*P*<0.05); score of gastritis: 7.0±0.0 vs 3.6±0.5 (*P*<0.05), 7.0±0.0 vs 2.7±0.5 (*P*<0.05); MPO activity (μmol H₂O₂/min/g tissue): 104.7±9.2 vs 9.0±2.3 (*P*<0.05), 133.5±15.0 vs 2.9±0.7 (*P*<0.05); PGE₂ synthesis (pg/mg wet weight/min): 299.2±81.5 vs 102.8±26.2 (*P*<0.05), 321.4±30.3 vs 11.9±4.8 (*P*<0.05).

CONCLUSION: Eradication of *H pylori* reduced gastric damage of NSAID-treated Mongolian gerbils. Rofecoxib caused less severe gastric damage than indomethacin in *H pylori*-eradicated gerbils.

© 2005 The WJG Press and Elsevier Inc. All rights reserved.

Key words: *Helicobacter pylori*; Gastric damage; NSAIDs

Chang CC, Chen SH, Lien GS, Lou HY, Hsieh CR, Fang CL, Pan S. Eradication of *Helicobacter pylori* significantly reduced gastric damage in nonsteroidal anti-inflammatory drug-treated Mongolian gerbils. *World J Gastroenterol* 2005; 11(1): 104-108 <http://www.wjgnet.com/1007-9327/11/104.asp>

INTRODUCTION

Helicobacter pylori is considered a major cause of acute and chronic gastritis, peptic ulcer disease, and is highly associated with the development of gastric mucosa associated lymphoid tissue lymphoma and gastric cancer^[1-3]. Both NIH and IARC issued statements on the importance of *H pylori* eradication and carcinogenic risks in patients with *H pylori* infection^[4,5]. Nonsteroidal anti-inflammatory drugs (NSAIDs) are probably the most common cause of gastroduodenal injury in the United States of America today. Approximately half the patients who regularly take NSAIDs have gastric erosions, and 15-30% reveal ulcers on endoscopy examination^[6]. In addition, severe side effects including gastrointestinal bleeding and perforation can be encountered after usage of aspirin or NSAIDs^[7-11]. Both *H pylori* and NSAIDs are the major causes of peptic ulcer. However, their interaction is complex and controversial, with studies showing inconsistent results. Hawkey *et al.*^[12] reported that, in long-term NSAID users with past or current peptic ulcers or troublesome dyspepsia, eradication of *H pylori* led to impaired healing of gastric ulcers, and did not affect the rate of development of peptic ulcers or dyspepsia over 6 mo. However, Chan *et al.*^[13,14] reported that eradication of *H pylori* before use of NSAIDs lowered the occurrence of NSAID-induced ulcers in patient without peptic ulcer or previous exposure to NSAIDs. Because the gerbil model is quite suitable for *in vivo* study of the pathogenesis of *H pylori*-induced gastric diseases, it exhibits pathological features that mimic those of human patients with *H pylori*^[15,16]. To examine the effect of eradication of *H pylori* prior to usage of NSAIDs, we investigated the gastric inflammatory activity, myeloperoxidase (MPO) activity and prostaglandin E₂ (PGE₂) production in *H pylori*-infected, *H pylori*-eradicated and *H pylori*-uninfected gerbils which were followed by giving indomethacin or rofecoxib.

MATERIALS AND METHODS

Animals

Male Mongolian gerbils (6-wk-old, 40-50 g) were purchased from Seac Yoshitomi (Fukuoka, Japan). They were kept in an isolated clean room at a regulated temperature (20-22 °C) and humidity (50-55%) in a 12/12 h light-dark cycle. Gerbils were fasted for 24 h before and 4 h after *H pylori* inoculation. Four hours after *H pylori* inoculation, they were afforded water and food.

H pylori preparation and inoculation

H pylori strains (ATCC 43504) were incubated in a brain-heart infusion broth containing 10% fetal bovine serum at 37 °C overnight under a microaerophilic atmosphere and allowed to grow to a density of 2.0×10⁸ colony-forming units (CFU)/mL. The culture broth was orally inoculated into gerbils at a dosage of 1.0 mL/animal. Normal animals received 1 mL of the medium only.

Eradication of *H pylori*

A "triple therapy" was performed. Amoxicillin, clarithromycin

and lansoprazole were suspended in 0.5% w/w carboxymethyl cellulose (CMC) sodium salt solution and administered orally twice a day for four days at doses of 3, 30, 10 mg/kg body weight, respectively. CMC as a vehicle was administered to *H pylori*-infected and *H pylori*-uninfected gerbils. The success rate of *H pylori* eradication is around 85.9%.

Administration of NSAIDs

Indomethacin (non-selective COX inhibitor) and rofecoxib (selective COX-2 inhibitor) were orally given to two different groups of gerbils at doses of 2 mg/kg and 10 mg/kg body weight once a day for 2 wk, respectively.

Diagnosis of *H pylori* infection or eradication

We performed *H pylori* culture and rapid urease test to confirm the existence of *H pylori*. The gerbils were sacrificed with ether anesthesia, and then their half-stomachs (right side) were excised. After approximately 50-100 g of the stomach was punched out for MPO activity examination, the rest part of the stomach was homogenized in 10 mL phosphate buffered saline with a Polytron, followed by dilution with the same buffer. Aliquots (100 μ L) of the dilutions were applied to Brucella agar plates containing 10% horse blood (Nippon Bio-Test Laboratories, Tokyo, Japan), 2.5 μ g/mL amphotericin B, 9 μ g/mL vancomycin, 0.32 μ g/mL polymyxin B, 5 μ g/mL trimethoprim and 50 μ g/mL 2, 3, 5-triphenyltetrazolium chloride. The plates were incubated at 37 °C under microaerophilic atmosphere (N₂ 850 mL/L, CO₂ 10 mL/L, O₂ 5%) for seven days. *H pylori* was identified as gold colonies in spiral shape under a microscope and positive for rapid urease test.

Determination of gastric inflammatory activity

Gross observation The stomachs were opened along the greater curvature and washed with phosphate buffered saline, spread gently and fixed with pins on a cork board. All the stomachs were determined by an experienced researcher who was unaware of the treatment of the animals. Under a dissecting microscope, variable sizes and types of gastric lesions were checked and recorded with a square grid.

Microscopic observation Half of each stomach (left side) was fixed in 10% formalin and embedded with paraffin. Four μ m thick sections were prepared and were stained with hematoxylin and eosin. The diagnosis of gastritis was made according to the modified criteria reported by Ohta *et al.*^[17] which was modified slightly from Rauwas *et al.*^[18]. The parameters of chronic active gastritis were as follows: lymphocyte infiltration (0: none, 1: mild infiltration to lamina propria, 2: moderate infiltration to lamina propria, 3: severe infiltration and lymphoid follicle formation), polymorphonuclear leukocyte infiltration (0: none, 1: the number of cells in lamina propria was <30 in the field of magnification \times 400, 2: 30-100/field, 3 >100/field), superficial erosions (0: none, 1: deletion of surface epithelial cells). The total score of these variables varied from 0 to 7, and was used as a measure of the activity of gastritis. Microscopic gastritis was classified as non-gastritis (score: 0), mild gastritis (scores: 1-3); moderate gastritis (scores: 4-5) and severe gastritis (scores: 6-7). An experienced pathologist determined the gastric pathology without awareness of the prior treatment.

Determination of PGE₂ synthesis and MPO activity

PGE₂ production in gastric mucosae of the gerbils was determined according to the method of Lee and Feldman^[19]. We punched out about 50-100 mg gastric specimen from the border of gastric antrum and corpus (right half side) in each gerbil. The specimen was placed in 50 mmol/L Tris HCl (pH 8.4) buffer and then minced with a pair of scissors. After the tissue samples were washed and resuspended in 2 mL of buffer, each sample was subjected to

vortex mixing at room temperature for 1 min to stimulate PGE₂ production, followed by centrifugation at 10 000 g for 15 s. The PGE₂ levels in the resulting supernatants were determined by means of an enzyme immunoassay (PGE₂ EIA kit; Cayman Chemicals, Ann Arbor, Michigan, USA). PGE₂ production was expressed as picograms of PGE₂ per minute per milligram of tissue.

After removal of supernatants for PGE₂ analysis, the MPO activity in the remaining tissue was determined by the method described by Takahashi and Keto^[20,21]. Each sample (approximately 50-100 mg) was first homogenized with a Polytron in 1.0 mL of 50 mmol/L phosphate buffer (pH 6.0) containing 0.5% hexadecyltrimethyl-ammonium bromide (Sigma), and then subjected to three sessions of freezing-thawing. Subsequently, the homogenates were centrifuged at 1 600 g for 10 min at 4 °C. After 5 μ L aliquots of each supernatant was mixed with 145 μ L of phosphate buffer (pH 6.0) containing 0.167 mg/mL *o*-dianisidine dihydrochloride (Sigma) and 0.0005% H₂O₂, the change in the rate of absorbance at 450 nm was measured with a microplate reader (Thermo Max; Molecular Devices, Sunnyvale, CA). The MPO activity was expressed as the degradation of H₂O₂ μ mol/min/g tissue.

Statistical analysis

Data was presented as mean \pm SE from 5 to 7 animals per group. Student's *t*-test and Fisher's exact test were used for comparison between two groups. *P*<0.05 was considered statistically significant.

RESULTS

Ratio of stomach weight to body weight

In indomethacin-treated gerbils, the ratio of stomach weight to body weight ($\times 10^3$) was 14.1 \pm 1.3, 10.5 \pm 0.3 and 9.0 \pm 0.3 in *H pylori* infected, *H pylori*-eradicated and *H pylori*-uninfected groups respectively (Figure 1). In rofecoxib treated gerbils, the ratio of stomach weight to body weight ($\times 10^3$) was 12.7 \pm 0.4, 10.1 \pm 0.3 and 8.1 \pm 0.4 respectively (Figure 1). Among gerbils treated with indomethacin or rofecoxib, the ratio of stomach weight to body weight increased significantly in *H pylori*-infected group than in *H pylori*-eradicated or *H pylori*-uninfected group (*P*<0.05). This data suggested that the ratio of stomach weight to body weight was decreased after *H pylori* eradication. Since the tissue weight was usually proportional to the inflammation, the stomach became less oedemata after *H pylori* eradication.

Hyperplastic area of stomach

In indomethacin-treated gerbils, hyperplastic area of the stomach (mm²) was 82.4 \pm 9.2, 13.8 \pm 3.5 and 0 in *H pylori*-infected, *H pylori*-eradicated and *H pylori*-uninfected groups, respectively. In rofecoxib treated gerbils, hyperplasia area of the stomach (mm²) was 30.5 \pm 5.1, 1.3 \pm 0.6 and 0 respectively (*P*<0.05, *H pylori* infected group vs *H pylori*-eradicated or *H pylori*-uninfected group) (Figure 2).

Gastric erosion and ulcer area of stomach

In indomethacin-treated gerbils, gastric erosion and ulcer areas of the stomach (mm²) were 14.4 \pm 4.9, 0.86 \pm 0.46 and 0 in *H pylori* infected, *H pylori*-eradicated and *H pylori*-uninfected groups, respectively (Figure 3). In rofecoxib-treated gerbils, those were 30.5 \pm 5.1, 1.3 \pm 0.6 and 0 in *H pylori* infected, *H pylori*-eradicated and *H pylori*-uninfected groups, respectively (Figure 3). Either treated with indomethacin or rofecoxib, more severe inflammation of the stomach was found in *H pylori*-infected group than in *H pylori*-eradicated or *H pylori*-uninfected group (*P*<0.05).

In addition, upper gastrointestinal bleeding was found in two out of seven gerbils (28.6%) in *H pylori*-infected and indomethacin treated groups. However, none of the gerbils suffered from upper gastrointestinal bleeding in other groups.

Score of chronic active gastritis

There was a more significant improvement of chronic active gastritis in *H pylori*-eradicated gerbils than in *H pylori*-infected gerbils, treated either with indomethacin or with rofecoxib ($P<0.05$) (Figure 4). The score of chronic active gastritis was shown in Table 1. No gastritis was noted in *H pylori*-uninfected gerbils treated with rofecoxib. Mild gastritis was found in *H pylori*-eradicated gerbils treated with rofecoxib and in some of *H pylori*-uninfected gerbils treated with indomethacin. Moderated gastritis was observed in *H pylori*-eradicated gerbils treated with indomethacin. Severe gastritis was observed in *H pylori*-infected gerbils.

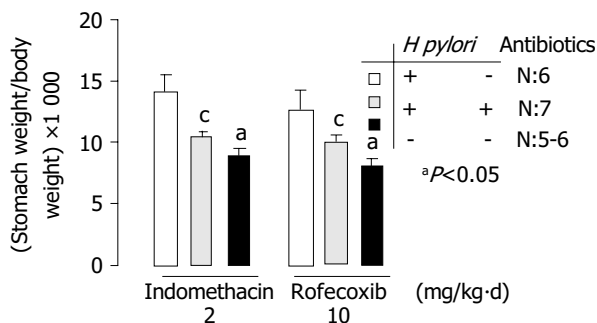


Figure 1 Ratio of stomach weight to body weight in *H pylori*-infected, *H pylori*-eradicated and *H pylori*-uninfected Mongolian gerbils. *H pylori*-infected, *H pylori*-eradicated and *H pylori*-uninfected Mongolian gerbils are shown as black bar, slash line bar and point bar respectively. ^a $P<0.05$ vs *H pylori*-eradicated, ^c $P<0.05$ vs *H pylori*-infected.

Table 1 Changes of gastric inflammation induced by indomethacin between *H pylori* infected, *H pylori*-eradicated and *H pylori*-uninfected gerbils (mean±SD)

	<i>H pylori</i> -infected	<i>H pylori</i> -eradicated	<i>H pylori</i> -uninfected	P
Stomach weight ratio (×1000)	14.1±1.3	10.5±0.3	9.0±0.3	<0.05 ^a <0.05 ^c
Hyperplasia area (mm ²)	82.4±9.2	13.9±3.5	0	<0.05 ^a <0.05 ^c
Erosion and ulcer area (mm ²)	14.4±4.9	0.9±0.5	0	<0.05 ^a <0.05 ^c
Score of gastritis	7.0±0.0	3.6±0.5	0.8±0.4	<0.05 ^a <0.05 ^c
MPO activity (μmol H ₂ O ₂ /min/g tissue)	104.7±9.2	8.9±2.3	7.8±2.5	<0.05 ^a <0.05 ^c
PGE ₂ synthesis (pg/mg wet weight/min)	299.2±81.5	102.8±26.2	9.6±1.3	<0.05 ^a <0.05 ^c

Stomach weight ratio: weight of stomach to weight of body ^a $P<0.05$, *H pylori*-infected vs *H pylori*-eradicated; ^c $P<0.05$, *H pylori*-infected vs *H pylori* uninfected.

Table 2 Changes of gastric inflammation induced by rofecoxib between *H pylori*-infected, *H pylori*-eradicated and *H pylori*-uninfected gerbils

	<i>H pylori</i> -infected	<i>H pylori</i> -eradicated	<i>H pylori</i> -uninfected	P
Stomach weight ratio (×1000)	12.8±0.4	10.1±0.3	8.1±0.4	<0.05 ^a <0.05 ^c
Hyperplasia area (mm ²)	30.5±5.1	1.3±0.6	0	<0.05 ^a <0.05 ^c
Erosion and ulcer area (mm ²)	1.3±0.6	0.4±0.3	0	<0.05 ^a <0.05 ^c
Score of gastritis	7.0±0.0	2.7±0.5	0	<0.05 ^a <0.05 ^c
MPO activity (μmol H ₂ O ₂ /min/g tissue)	133.5±15.0	2.9±0.7	6.6±1.7	<0.05 ^a <0.05 ^c
PGE ₂ synthesis (pg/mg wet weight/min)	321.4±30.3	11.9±4.8	25.9±15.9	<0.05 ^a <0.05 ^c

Stomach weight ratio: weight of stomach to weight of body ^a $P<0.05$, *H pylori*-infected vs *H pylori*-eradicated; ^c $P<0.05$, *H pylori*-infected vs *H pylori* uninfected.

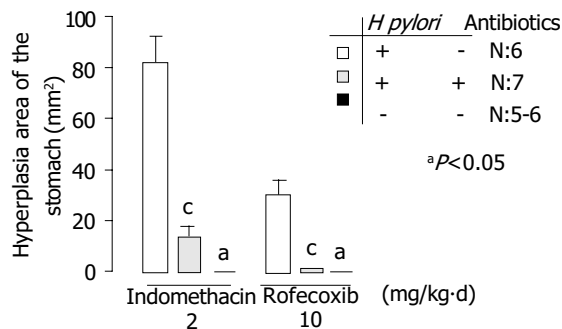


Figure 2 Hyperplastic area of the stomach in *H pylori*-infected, *H pylori*-eradicated and *H pylori*-uninfected Mongolian gerbils. *H pylori*-infected, *H pylori*-eradicated and *H pylori*-uninfected Mongolian gerbils are shown as black bar, slash line bar and point bar, respectively. ^a $P<0.05$ vs *H pylori*-eradicated, ^c $P<0.05$ vs *H pylori*-infected.

MPO activity

MPO activity is demonstrated in Figure 5. A significantly lower activity of MPO was found in *H pylori*-uninfected or *H pylori*-eradicated groups compared to *H pylori*-infected groups ($P<0.05$). The data of each group are shown in Tables 1 and 2.

PGE₂ synthesis

Figure 6 demonstrates PGE₂ synthesis in indomethacin- or rofecoxib-treated gerbils. PGE₂ synthesis in *H pylori*-eradicated gerbils was decreased significantly in comparison with that in *H pylori*-infected gerbils ($P<0.05$). The data of each group are shown in Tables 1 and 2.

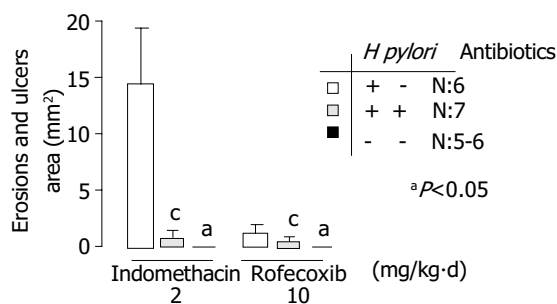


Figure 3 Gastric erosion and ulcer area in *H pylori*-infected, *H pylori*-eradicated and *H pylori*-uninfected Mongolian gerbils. *H pylori*-infected, *H pylori*-eradicated and *H pylori*-uninfected Mongolian gerbils are shown as black bar, slash line bar and point bar respectively. ^a $P < 0.05$ vs *H pylori*-eradicated, ^c $P < 0.05$ vs *H pylori*-infected.

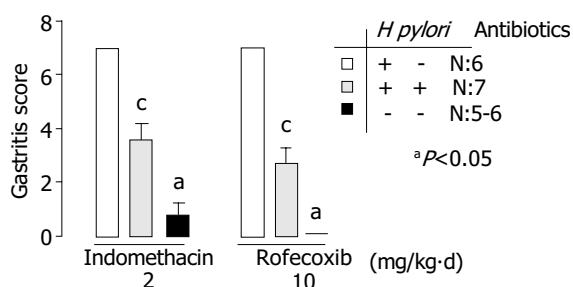


Figure 4 Scores of chronic gastritis in *H pylori*-infected, *H pylori*-eradicated and *H pylori*-uninfected Mongolian gerbils. *H pylori*-infected, *H pylori*-eradicated and *H pylori*-uninfected Mongolian gerbils are shown as black bar, slash line bar and point bar, respectively. ^a $P < 0.05$ vs *H pylori*-eradicated, ^c $P < 0.05$ vs *H pylori*-infected.

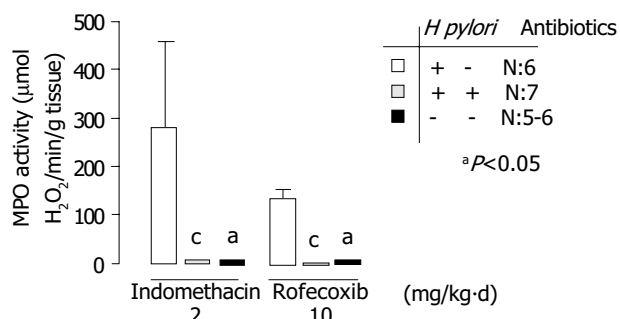


Figure 5 MPO activity in *H pylori*-infected, *H pylori*-eradicated and *H pylori*-uninfected Mongolian gerbils. *H pylori*-infected, *H pylori*-eradicated and *H pylori*-uninfected Mongolian gerbils are shown as black bar, slash line bar and point bar, respectively. ^a $P < 0.05$ vs *H pylori*-eradicated, ^c $P < 0.05$ vs *H pylori*-infected.

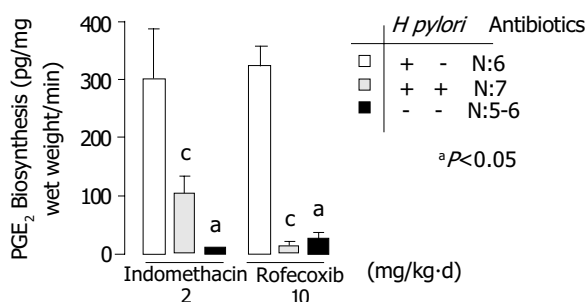


Figure 6 PGE₂ synthesis of gastric mucosa in *H pylori*-infected, *H pylori*-eradicated and *H pylori*-uninfected Mongolian gerbils. *H pylori*-infected, *H pylori*-eradicated and *H pylori*-uninfected Mongolian gerbils are shown as black bar, slash line bar and point bar, respectively. ^a $P < 0.05$ vs *H pylori*-eradicated, ^c $P < 0.05$ vs *H pylori*-infected.

Comparison of the effects of gastric damage induced by indomethacin and rofecoxib

***H pylori* infection** Indomethacin-treated gerbils had more severe gastric mucosa damages than rofecoxib-treated gerbils on the hyperplastic area, erosion and ulcer area of the stomach ($P < 0.05$). There was no statistically significant difference between indomethacin-treated and rofecoxib-treated gerbils in the score of chronic active gastritis, MPO activity and PGE₂ synthesis of the stomach ($P > 0.05$).

***H pylori* eradication** Rofecoxib was significantly superior to indomethacin on the less severe gastric mucosa damage in *H pylori*-eradicated gerbils ($P < 0.05$). There was also less severity on the erosion and ulcer area of the stomach and score of chronic active gastritis in rofecoxib-treated gerbils than in indomethacin-treated gerbils, although there was no statistically significant difference ($P > 0.05$).

DISCUSSION

This study clearly demonstrates that eradication of *H pylori* could significantly reduce gastric mucosa damage in Mongolian gerbils treated with indomethacin or rofecoxib.

Clinically, it has not been clear whether *H pylori* infection aggravates gastric mucosa injury in long-term NSAID users. Santucci *et al.*^[22] found that more severe gastroduodenal mucosa lesions developed after a four-week NSAID medication in *H pylori*-infected patients than in *H pylori*-uninfected patients. However, other studies showed no evidence of remarkable injury when *H pylori* infection coexisted with NSAID use. Graham *et al.*^[23] reported gastric erosions in 34% and bleeding in 32% of patients who also had *H pylori* infection, representing a lower incidence than in patients without *H pylori* infection (57% and 61%, respectively). Recently, several investigators reported more severe gastric damage in *H pylori*-infected and NSAIDs-treated gerbils. Takahashi *et al.*^[24] suggested that NSAIDs synergistically aggravated gastric lesions in moderate *H pylori* infection, but not in severe gastritis. In addition, Yoshida *et al.*^[25] reported that *H pylori* infection potentiated aspirin-induced gastric mucosal injury in Mongolian gerbils.

What most physicians are concerned about is the necessity for patients to receive anti-*H pylori* therapy before using NSAIDs. It remains still controversial. Two important clinical studies gave conflicting results. Hawkey and colleagues^[12] reported that, in long-term NSAID users with past or current peptic ulcers or troublesome dyspepsia, eradication of *H pylori* led to impaired healing of gastric ulcers, and did not affect the rate of development of peptic ulcers or dyspepsia in over 6 mo. However, Chan and colleagues^[14] reported that eradication of *H pylori* before usage of NSAIDs lowered the occurrence of NSAID-induced ulcers in patients without peptic ulcer or previous exposure to NSAIDs. In our study, we used the gerbil model which was consecutively treated with NSAIDs (indomethacin or rofecoxib) to investigate the severity of gastric inflammation among *H pylori*-eradicated, *H pylori*-infected and *H pylori*-uninfected groups.

From gross observation, the most severe gastric mucosa damage was found in *H pylori*-infected and indomethacin treated groups. Around 28.6% of them suffered from gastric ulcer with bleeding. However, there was no gastric ulcer with bleeding in *H pylori*-infected and rofecoxib treated groups. Less severe damage of gastric mucosa caused by rofecoxib might be due to the selective COX-2 inhibition. The most important finding in our study was that eradication of *H pylori* prior to administration of NSAIDs (indomethacin or rofecoxib) could significantly reduce gastric damage from macroscopic and/or microscopic observations.

MPO activity in gastric mucosa is an indicator of infiltration

of neutrophils into mucosae. Keto and colleagues^[26] reported that MPO activity was lower in indomethacin-treated gerbils than in *H pylori* infected and indomethacin-treated gerbils. It seems that *H pylori* infection may aggravate gastric mucosa damage in gerbils treated with NSAIDs. Perhaps, eradication of *H pylori* may lead to improvement of mucosal inflammation. Keto *et al.*^[21] proved that MPO activity was lower in *H pylori*-eradicated gerbils than in controls. However, we found a significant reduction of MPO activity in *H pylori*-eradicated gerbils treated with NSAIDs (indomethacin or rofecoxib).

PGE₂ might increase blood flow, secretion of mucus and bicarbonate, inhibit acid secretion, and directly protect gastric cells against toxic stimuli^[27]. In response to *H pylori* infection, COX-2 expression is absent in normal mucosa, but is profoundly induced in *H pylori*-positive gastritis. COX-2 expression was higher in *H pylori* infected gerbils than in normal controls. The COX-2 level was higher in gerbils infected with *H pylori* for 12 wk than in those are infected with *H pylori* for 12 wk^[24]. The production of PGE₂ in the stomach of gerbils was significantly higher in *H pylori*-infected groups than in normal controls^[24]. In our study, we observed a significant reduction of PGE₂ production in gastric mucosa of gerbils after consecutive treatment with NSAIDs (indomethacin or rofecoxib) in *H pylori*-eradicated group in comparison with that in *H pylori*-infected group.

Selective COX-2 inhibitors are believed to cause less severe gastroduodenal mucosa damage than non-selective COX inhibitors. Our results have shown that selective COX-2 inhibitors are partially superior to conventional NSAIDs in *H pylori*-infected and *H pylori*-eradicated gerbils.

It is very important to elucidate the interaction between *H pylori* and NSAIDs on the injury of gastric mucosa and the necessity of *H pylori* eradication before using NSAIDs. In conclusion, *H pylori* infection profoundly aggravates gastric mucosa damage following the use of NSAIDs (indomethacin or rofecoxib). Eradication of *H pylori* can significantly reduce gastric mucosa damage in consecutive NSAIDs-treated Mongolian gerbils.

ACKNOWLEDGEMENTS

The authors thank Mr. Kenji Nakjima, Miss Keiko Kanatani, Dr. Kikuko Amagase and Professor Susumu Okabe for their instructions and help.

REFERENCES

- Anonymous. Unidentified curved bacilli on gastric epithelium in active chronic gastritis. *Lancet* 1983; **1**: 1273-1275
- Hentschel E, Brandstatter G, Dragosics B, Hirschl AM, Nemeč H, Schutze K, Taufer M, Wurzer H. Effect of ranitidine and amoxicillin plus metronidazole on the eradication of *Helicobacter pylori* and the recurrence of duodenal ulcer. *N Engl J Med* 1993; **328**: 308-312
- Parsonnet J, Friedman GD, Vandersteen DP, Chang Y, Vogelstein JH, Orentreich N, Sibley RK. *Helicobacter pylori* infection and the risk of gastric carcinoma. *N Engl J Med* 1991; **325**: 1127-1131
- NIH Consensus Development Conference. *Helicobacter pylori* in peptic ulcer diseases. *JAMA* 1994; **272**: 65-69
- IARC monographs on the evaluation of carcinogenic risks to human. schistosomes, liver flukes and *Helicobacter pylori*. Geneva: WHO, International agency for research on cancer. *Monography* 1994; **61**: 177-220
- Laine L. Approaches to nonsteroidal anti-inflammatory drug use in the high-risk patient. *Gastroenterology* 2001; **120**: 594-606
- Lanas A, Serrano P, Bajador E, Esteve F, Benito R, Sainz R. Evidence of aspirin use in both upper and lower gastrointestinal perforation. *Gastroenterology* 1997; **112**: 683-689
- Bjarnason I, Hayllar J, MacPherson AJ, Russell AS. Side effects of nonsteroidal anti-inflammatory drugs on the small and large intestine in humans. *Gastroenterology* 1993; **104**: 1832-1847
- Garcia Rodriguez LA, Jick H. Risk of upper gastrointestinal bleeding and perforation associated with individual nonsteroidal anti-inflammatory drugs. *Lancet* 1994; **343**: 769-772
- Allison MC, Howatson AG, Torrance CJ, Lee FD, Russell RI. Gastrointestinal damage associated with the use of nonsteroidal anti-inflammatory drugs. *N Engl J Med* 1992; **327**: 749-754
- Laine L. Nonsteroidal anti-inflammatory drug gastropathy. *Gastrointest Endosc Clin N Am* 1996; **6**: 489-504
- Hawkey CJ, Tulassay Z, Szczepanski L, van Rensburg CJ, Filipowicz-Sosnowska A, Lanas A, Wason CM, Peacock RA, Gillon KR. Randomised controlled trial of *Helicobacter pylori* eradication in patients on non-steroidal anti-inflammatory drugs: HELP NSAIDs study. Helicobacter Eradication for lesion prevention. *Lancet* 1998; **352**: 1016-1021
- Chan FK, Chung SC, Suen BY, Lee YT, Leung WK, Leung VK, Wu JC, Lau JY, Hui Y, Lai MS, Chan HL, Sung JJ. Preventing recurrent upper gastrointestinal bleeding in patients with *Helicobacter pylori* infection who are taking low-dose aspirin or naproxen. *N Engl J Med* 2001; **344**: 967-973
- Chan FK, To KF, Wu JC, Yung MY, Leung WK, Kwok T, Hui Y, Chan HL, Chan CS, Hui E, Woo J, Sung JJ. Eradication of *Helicobacter pylori* and risk of peptic ulcers in patients starting long-term treatment with non-steroidal anti-inflammatory drugs: A randomised trial. *Lancet* 2002; **359**: 9-13
- Hirayama F, Takagi S, Kusuhara H, Iwao E, Yokoyama Y, Ikeda Y. Induction of gastric ulcer and intestinal metaplasia in mongolian gerbils infected with *Helicobacter pylori*. *J Gastroenterol* 1996; **31**: 755-757
- Hirayama F, Takagi S, Yokoyama Y, Iwao E, Ikeda Y. Establishment of gastric *Helicobacter pylori* infection in Mongolian gerbils. *J Gastroenterol* 1996; **31**(Suppl 9): 24-28
- Ohta T, Shibata H, Kawamori T, Iimuro M, Sugimura T, Wakabayashi K. Marked reduction of *Helicobacter pylori*-induced gastritis by urease inhibitors, acetohydroxamic acid and flurofamide, in Mongolian gerbils. *Biochem Biophys Res Commun* 2001; **285**: 728-733
- Rauws EA, Langenberg W, Houthoff HJ, Zanen HC, Tytgat GN. Campylobacter pyloridis-associated chronic active antral gastritis: A prospective study of its prevalence and the effects of antibacterial and antiulcer treatment. *Gastroenterology* 1988; **94**: 33-40
- Lee M, Feldman M. Age-related reductions in gastric mucosal prostaglandin levels increase susceptibility to aspirin-induced injury in rats. *Gastroenterology* 1994; **107**: 1746-1750
- Takahashi S, Keto Y, Fujita H, Muramatsu H, Nishino T, Okabe S. Pathological changes in the formation of *Helicobacter pylori*-induced gastric lesions in Mongolian gerbils. *Dig Dis Sci* 1998; **43**: 754-765
- Keto Y, Takahashi S, Okabe S. Healing of *Helicobacter pylori*-induced gastric ulcers in Mongolian gerbils: combined treatment with omeprazole and clarithromycin. *Dig Dis Sci* 1999; **44**: 257-265
- Santucci L, Fiorucci S, Patoia L, Di Matteo FM, Brunori PM, Morelli A. Severe gastric mucosal damage induced by NSAIDs in healthy subjects is associated with *Helicobacter pylori* infection and high levels of serum pepsinogens. *Dig Dis Sci* 1995; **40**: 2074-2080
- Graham DY, Lidsky MD, Cox AM, Evans DJ Jr, Evans DG, Alpert L, Klein PD, Sessoms SL, Michaletz PA, Saeed ZA. Long-term nonsteroidal anti-inflammatory drug use and *Helicobacter pylori* infection. *Gastroenterology* 1991; **100**: 1653-1657
- Takahashi S, Fujita T, Yamamoto A. Nonsteroidal anti-inflammatory drug-induced acute gastric injury in *Helicobacter pylori* gastritis in Mongolian gerbils. *Eur J Pharmacol* 2000; **406**: 461-468
- Yoshida N, Sugimoto N, Hirayama F, Nakamura Y, Ichikawa H, Naito Y, Yoshikawa T. *Helicobacter pylori* infection potentiates aspirin induced gastric mucosal injury in Mongolian gerbils. *Gut* 2002; **50**: 594-598
- Keto Y, Ebata M, Tomita K, Okabe S. Influence of *Helicobacter pylori* infection on healing and relapse of acetic acid ulcers in Mongolian gerbils. *Dig Dis Sci* 2002; **47**: 837-849
- Eberhart CE, Dubois RN. Eicosanoids and the gastrointestinal tract. *Gastroenterology* 1995; **109**: 285-301