



Case report

Acute pulmonary edema from unrecognized high irrigation pressure in hysteroscopy: a report of two cases[☆]

Ming-Hui Hsieh MD (Resident), Ta-Liang Chen MD, PhD (Professor),
Yu-Hua Lin MD (Staff Anesthesiologist),
Chuen-Chau Chang MD, PhD (Assistant Professor),
Chao-Shun Lin MD (Staff Anesthesiologist),
Yuan-Wen Lee MD (Staff Anesthesiologist)*

Department of Anesthesiology, Taipei Medical University Hospital, Taipei, Taiwan 11031

Received 11 April 2007; revised 23 May 2008; accepted 29 May 2008

Keywords:

Hysteroscopy;
Pulmonary edema

Abstract After two consecutive patients underwent hysteroscopy that was complicated by pulmonary edema, the pneumatically inflated pressure cuff machine was checked and found that the pressure gauge was in error, with actual pressure being twice that of the recorded number. High irrigation pressures with a seemingly normal amount of irrigation fluid may induce acute pulmonary edema.
© 2009 Elsevier Inc. All rights reserved.

1. Introduction

The use of the hysteroscope in modern gynecological practice continues to develop as a diagnostic and management tool for intrauterine disease. Complications arising from hysteroscopy are relatively rare. They occur more frequently with operative hysteroscopy than with diagnostic hysteroscopy. One of the reported risks of hysteroscopy is intravasation of uterine distension fluid. Volume overload may cause pulmonary edema and congestive heart failure. Water intoxication may lead to hyponatremia, hypoosmolarity, and cerebral edema. Therefore, all possible measures should be taken to prevent it or else treat it early.

Two cases of acute pulmonary edema from hysteroscopy with unrecognized high irrigation pressure are presented.

2. Case report

2.1. Case 1

A 40-year-old, 65 kg woman was scheduled to undergo hysteroscopic surgery for possible intrauterine synechia. She had a surgical history of myomectomy and her past medical history was unremarkable. Preoperative laboratory test showed hemoglobin (Hb) of 14.1 g/dL. Her pre-anesthesia vital signs were blood pressure (BP) 134/89 mmHg, heart rate (HR) 80 bpm, and oxygen saturation as determined by pulse oximetry (SpO₂) of 100%.

General anesthesia was induced with intravenous (IV) administration of fentanyl 50 µg, lidocaine 50 mg, and propofol 150 mg. Insertion of a Laryngeal Mask Airway

[☆] Support was provided solely from institutional and department sources.

* Corresponding author. Tel.: +886 2 2737 2181x8310; fax: +886 2 27367344.

E-mail address: drkevin66@yahoo.com.tw (Y.-W. Lee).

(LMA) was done smoothly after succinylcholine 50 mg IV was given. Anesthesia was maintained with 2% sevoflurane in oxygen. Controlled ventilation was provided until spontaneous respiration resumed, at which time the ventilation mode was changed to manually assisted ventilation for the rest of the case. Surgery was carried out with a monopolar current resectoscope. Ten percent dextrose solution was used for uterine distension, and it was infused by compressing the 500 mL bag with a pneumatically inflated pressure cuff registered at a pressure of 100 mmHg. Hysteroscopy showed endometrial polyps and intrauterine synechia. During the 40-minute operative period, the patient received 300 mL of Ringer's lactate solution IV. At the end of the procedure, her SpO₂ suddenly decreased to 85% on 100% oxygen; the patient bit down on the LMA, which then could not be removed. Succinylcholine 50 mg IV was given and endotracheal intubation was performed quickly on one attempt. After endotracheal intubation and mechanical ventilation with 100% oxygen, her SpO₂ improved to 100%. However, a large amount of pinkish, frothy sputum was aspirated from the endotracheal tube and rales were heard over bilateral lung fields. Chest radiography showed infiltration typical of pulmonary edema (Fig. 1), and furosemide 20 mg IV was given. Transvaginal aspiration of ascitic fluid was performed through the cul de sac by the surgeon, from which 900 mL of fluid was collected. Arterial blood gas (ABG) analysis done immediately after intubation showed pH 7.192, PCO₂ 56.2 mmHg, PO₂ 66 mmHg, sodium 126 mmol/L, potassium 4.3 mmol/L, and glucose 679 g/dL. Another 20 mg of furosemide was given. Urine output over the next two hours was 450 mL. A second ABG

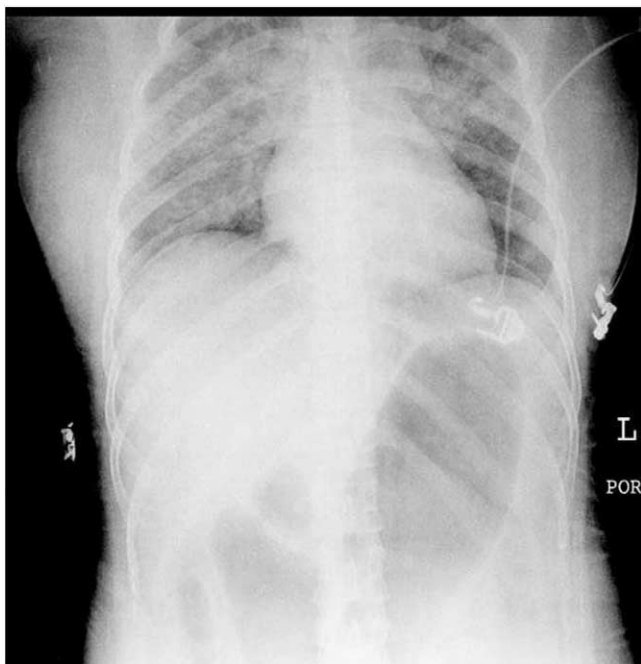


Fig. 1 Case 1 chest radiograph showing butterfly infiltration typical of pulmonary edema.

analysis showed pH 7.264, PCO₂ 56.4 mmHg, PO₂ 325 mmHg, sodium 135 mmol/L, and potassium 3.8 mmol/L. The patient was then transferred from the operating room to the intensive care unit (ICU) for close observation and care. Total urine output on that day was 1,390 mL. Chest radiography showed improvement of the pulmonary edema, while ABG analysis showed pH 7.423, PCO₂ 31.6 mmHg, and PO₂ 122.3 mmHg on the next day. Her trachea was extubated and she was moved from the ICU to the ward. One day later, she was discharged home with no sequelae.

2.2. Case 2

A 29-year-old, 54 kg woman was scheduled for hysteroscopy for dysmenorrhea. Her medical history was unremarkable. Preoperative laboratory values included Hb 13.6 g/dL. Preoperative vital signs were BP 112/72 mmHg, HR 61 bpm, and SpO₂ 100%.

General anesthesia was induced with fentanyl 50 µg, lidocaine 40 mg, and propofol 130 mg. After succinylcholine 40 mg IV was given, the LMA was inserted smoothly. Anesthesia was maintained with 100% oxygen and 2% sevoflurane. Ventilation was controlled until spontaneous respiration resumed. Surgery was performed with a monopolar current resectoscope. Ten percent dextrose irrigation fluid was instilled for uterine distension by compressing the bag with a pneumatically inflated pressure cuff at a registered pressure of 75 mmHg. Hysteroscopy showed submucosal myoma and myomectomy was performed smoothly. During the 90-minute operative period, 4,000 mL of 10% dextrose irrigation fluid was used, with 2,000 mL returned, and 400 mL of normal saline solution IV was given. Intraoperative vital signs included BP 80 to 90 mmHg systolic, 40 to 50 mmHg diastolic; and HR 50 to 60 bpm. At the end of surgery, the LMA was removed smoothly without any respiratory distress. The patient was then sent to the postanesthesia care unit where she complained of chest tightness and coughed out frothy, pinkish sputum. Her SpO₂ decreased to 96% with the LMA (O₂ flow, 6 L/min). Arterial blood gas analysis showed pH 7.375, PCO₂ 37 mmHg, PO₂ 69 mmHg, sodium 135 mmol/L, potassium 3.3 mmol/L, glucose > 600 g/dL, and Hb 13.6 g/dL. Chest radiography showed pulmonary edema (Fig. 2). Furosemide 20 mg, morphine two mg, and regular insulin 5 units were all administered IV. Urine output over the next 90 minutes was 600 mL and the patient gradually felt better. At that time, ABG analysis showed pH 7.349, PCO₂ 38.9 mmHg, PO₂ 115 mmHg, sodium 136 mmol/L, potassium 3.0 mmol/L, glucose 72 g/dL, and Hb 12.6 g/dL. Oxygen saturation was 99% to 100% with face mask, with oxygen flow of 6 L/min. Postoperative vital signs were stable and she was transferred to the ward for postoperative care. On the next day, the patient was discharged home without problem.

The pneumatically inflated pressure cuff machine was checked, and the pressure gauge was found to be in error, with the actual pressure being double that of the recorded figures.

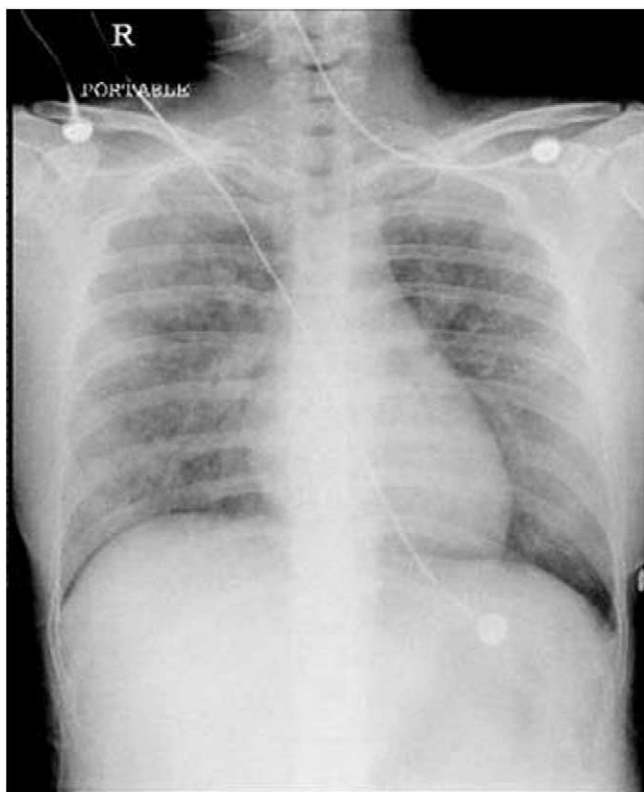

Fig. 2 Case 2 chest radiograph showing pulmonary edema.

Therefore, in Case 1, irrigation pressure during hysteroscopy was 200 mmHg and in Case 2, it was 150 mmHg.

3. Discussion

Hysteroscopic procedures now are the preferred treatment for dysfunctional uterine bleeding, menorrhagia, and myoma. Distension of the uterine cavity and establishment of a continuous intrauterine pressure are basic requirements for clear visualization of intrauterine structures and efficient surgical procedures. Low-viscosity fluids are most commonly used as distension media for operative hysteroscopy because of their relative safety and compatibility with the continuous flow resectoscope [1-4]. Low-viscosity media are divided into two groups according to their tonicity and electrolyte content: (1) hypotonic or hypertonic electrolyte-free media and (2) isotonic electrolyte-containing media [5]. Absorption of a large volume of electrolyte-free, low-viscosity fluid may result in volume overload with water intoxication. The absorption may occur by various mechanisms, including (1) directly into open vascular structures during surgical resection, (2) across the walls of the endometrium, and (3) via the fallopian tubes with absorption from the peritoneum [6,7]. Volume overload may cause pulmonary edema, and water intoxication may lead to hyponatremia, hyposmolality, and cerebral edema.

In our two cases, the irrigation fluid used was 10% dextrose water with irrigation pressure created by compressing the bag with a pneumatically inflated pressure cuff. No intrauterine pressure monitor or controlled irrigation infusion pump was used during the operation. The irrigation pressure registered below 100 mmHg. The amount of absorption of 10% dextrose water was about 1,000 mL in Case 1 and 2,000 mL in Case 2. However, severe pulmonary edema with rapid hypotonic fluid overload also was noted in Case 1. The pulmonary edema was mild in Case 2 even if the amount of fluid absorption was twice what it should have been. Therefore, we checked the irrigation pressure system and found that the pressure gauge was inaccurate and the actual value was twice the amount necessary. The large amount of irrigation fluid absorption is a predisposing factor for acute pulmonary edema in hysteroscopy but irrigation pressure is also significant. The high irrigation pressure with a normal amount of irrigation fluid might induce acute pulmonary edema.

Increased distension pressure, a prolonged surgical procedure, open vascular channels on the endometrial surface due to ablation or resection of endometrium, myomas, or septa, uterine perforation, or cervical laceration all result in increased risk of fluid overload [8]. Maintaining equilibrium between women's intrauterine pressures and mean arterial pressures (MAPs) decreases the risk of absorption of uterine distension fluid into the vasculature and fluid overload [9]. If intrauterine pressure was higher than MAP, the amount of fluid absorption increases. In our two cases, noninvasive BP values were recorded every 5 minutes intraoperatively, but no intrauterine pressure monitor was used. Independent variables that might influence intrauterine pressure include (1) height of the fluid reservoir or the pressure setting of the pump, (2) type of hysteroscope, (3) degree of cervical dilatation, and (4) outflow valve condition [10]. Intrauterine pressure should be limited so as to prevent fluid overload. McLucas recommends that infusion pressure be limited to 60 cm H₂O [11]. However, Istre et al. state that intrauterine pressure up to 100 mmHg is safe [12]. Devices used to control intrauterine pressure may decrease the amount of fluid absorption but do not eliminate the risk of venous air embolus [13].

Beside fluid overload, pulmonary edema also may be attributed to acute airway obstruction at the end of surgery [14]. In acute airway obstruction, the patient inspires against an obstruction. Inspiratory effort against airway obstruction allows the markedly negative intrathoracic pressure to be transmitted to the perivascular interstitium, thus facilitating fluid movement into this compartment [15]. Our Case 1 patient developed respiratory distress at the end of the hysteroscopic procedure after biting down on the LMA. The possibility of postobstructive pulmonary edema cannot be ruled out in the patient.

Pulmonary edema is a known complication of hysteroscopy. The anesthesiologist and gynecologist should maintain constant communication about fluid input and output to

prevent complications such as fluid overload. Meticulous calculation of intraoperative fluid balance and maintenance of proper intrauterine pressure are equally important, as high irrigation pressure with a seemingly normal amount of irrigation fluid may induce acute pulmonary edema.

References

- [1] Agraharkar M, Agraharkar A. Posthysteroscopic hyponatremia: evidence for a multifactorial cause. *Am J Kidney Dis* 1997;30:717-9.
- [2] Arieff AI. Management of hyponatraemia. *BMJ* 1993;307(6899):305-8.
- [3] Amin-Hanjani S, Good JM. Pyometra after endometrial resection and ablation. *Obstet Gynecol* 1995;85(5 Pt 2):893-4.
- [4] Arieff AI, Ayus JC. Endometrial ablation complicated by fatal hyponatremic encephalopathy. *JAMA* 1993;270:1230-2.
- [5] Cooper JM, Brady RM. Intraoperative and early postoperative complications of operative hysteroscopy. *Obstet Gynecol Clin North Am* 2000;27:347-66.
- [6] Magos AL, Baumann R, Lockwood GM, Turnbull AC. Experience with the first 250 endometrial resections for menorrhagia. *Lancet* 1991;337(8749):1074-8.
- [7] Pyper RJ, Haeri AD. A review of 80 endometrial resections for menorrhagia. *Br J Obstet Gynaecol* 1991;98:1049-54.
- [8] Murdoch JA, Gan TJ. Anesthesia for hysteroscopy. *Anesthesiol Clin North America* 2001;19:125-40.
- [9] Bennett KL, Ohrmundt C, Maloni JA. Preventing intravasation in women undergoing hysteroscopic procedures. *AORN J* 1996;64:792-9.
- [10] Vulgaropulos SP, Haley LC, Hulka JF. Intrauterine pressure and fluid absorption during continuous flow hysteroscopy. *Am J Obstet Gynecol* 1992;167:386-91.
- [11] McLucas B. Intrauterine applications of the resectoscope. *Surg Gynecol Obstet* 1991;172:425-31.
- [12] Istre O, Skajaa K, Schjoensby AP, Forman A. Changes in serum electrolytes after transcervical resection of endometrium and submucous fibroids with use of glycine 1.5% for uterine irrigation. *Obstet Gynecol* 1992;80:218-22.
- [13] Grove JJ, Shinaman RC, Drover DR. Noncardiogenic pulmonary edema and venous air embolus as complications of operative hysteroscopy. *J Clin Anesth* 2004;16:48-50.
- [14] Guffin TN, Har-el G, Sanders A, Lucente FE, Nash M. Acute postobstruction pulmonary edema. *Otolaryngol Head Neck Surg* 1995;112:235-7.
- [15] Timby J, Reed C, Zeilender S, Glauser FL. "Mechanical" causes of pulmonary edema. *Chest* 1990;98:973-9.