

## Postauricular Nodular Fasciitis

Chun-Ding Huang, Yun-Ho Lin and Fei-Peng Lee, Professor  
*Otolaryngology -- Head and Neck Surgery* 2007 137: 164  
DOI: 10.1016/j.otohns.2007.03.025

The online version of this article can be found at:  
<http://oto.sagepub.com/content/137/1/164>

---

Published by:



<http://www.sagepublications.com>

On behalf of:



AMERICAN ACADEMY OF  
OTOLARYNGOLOGY-  
HEAD AND NECK SURGERY

F O U N D A T I O N

[American Academy of Otolaryngology- Head and Neck Surgery](http://www.aao-hns.org)

**Additional services and information for *Otolaryngology -- Head and Neck Surgery* can be found at:**

**Email Alerts:** <http://oto.sagepub.com/cgi/alerts>

**Subscriptions:** <http://oto.sagepub.com/subscriptions>

**Reprints:** <http://www.sagepub.com/journalsReprints.nav>

**Permissions:** <http://www.sagepub.com/journalsPermissions.nav>

## CLINICAL PHOTOGRAPHS

# Postauricular nodular fasciitis

Chun-Ding Huang, MD, Yun-Ho Lin, DDS, MS, and Fei-Peng Lee, MD,  
Taipei, Taiwan

An 18-year-old male had a tender mass over the left postauricular area, which rapidly grew over a 3-week period. A local physician suspected a large, infected sebaceous cyst and referred the patient to us for further treatment. There was no history of antecedent trauma. The mass was elastic, smooth-surfaced, and brownish, and measured  $4 \times 2.5 \times 2$  cm (Fig 1). Head and neck examination revealed no other abnormality. Incision and drainage were performed but no pus fluid was found inside. Therefore, a biopsy was taken and the pathological examination confirmed the diagnosis of nodular fasciitis. Head and neck computed tomography (CT) revealed a well-defined, superficial, soft tissue mass over the left postauricular region.

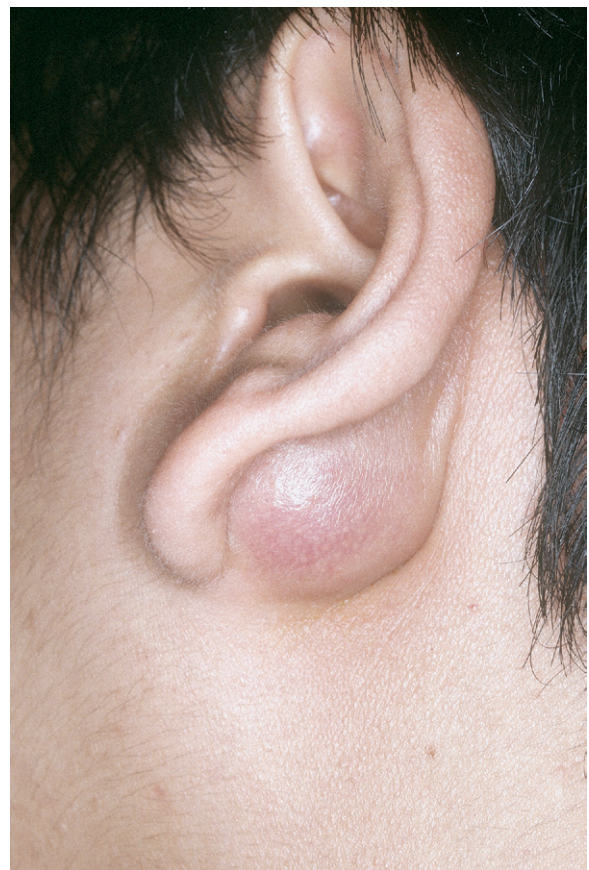Surgery was performed by using a Y-shape incision along the earlobe under general anesthesia. Ulcerative skin on the tumor surface, which had developed after the previous incision, was removed and sent for biopsy. The entire tumor along with some superficial tissue of the left parotid gland was excised successfully without facial nerve dissection. Histopathological analysis of the tumor (Fig 2) was consistent with a fibrous lesion with loosely arranged spindle cells in a myxoid stroma. The final diagnosis was nodular fasciitis. The postoperative course was uneventful and there was no recurrence 3 years after the operation.

## DISCUSSION

Nodular fasciitis, which was first described by Konwaller et al in 1955, is also known as pseudosarcomatous fasciitis, pseudosarcomatous fibromatosis, proliferative fasciitis, and infiltrative fasciitis.<sup>1</sup> Nodular fasciitis is a reactive rather than neoplastic process. The most common clinical manifestation of nodular fasciitis is a rapidly growing solid, or cystic, mass on an extremity in a young adult; it is usually associated with pain and tenderness.<sup>2</sup> The possibility of nodular fasciitis needs to be considered, especially when these symptoms occur along with a history of trauma. Furthermore, nodular fasciitis is usually not associated with multiple lesions.

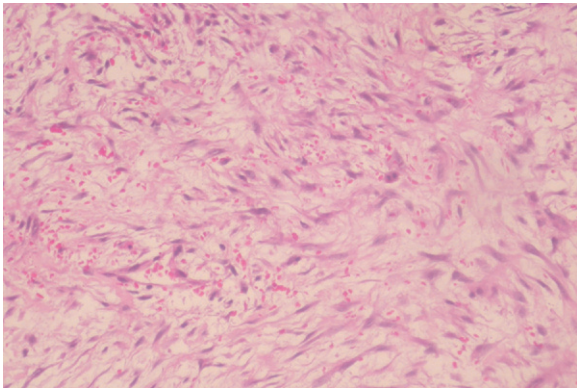
The most common locations in adults are the upper extremities (48%), followed by the trunk (20%), head and

neck (15%-20%), and lower extremities (15%).<sup>2</sup> Interestingly, nodular fasciitis is even more rarely found in the auricular region. Thompson et al<sup>3</sup> have done a retrospective study of 50 cases of auricular nodular fasciitis. They observed various commonalities in disease symptoms and pathology among nodular fasciitis patients. Their study included 22 female and 28 male subjects, ranging from ages 1 to 76 years with a mean of 27.4 years. Ninety-eight percent of patients had a mass lesion. Tumor size ranged



**Figure 1** The tumor, which showed a smooth surface with brown color, was located at the left postauricular region.

Received December 9, 2006; accepted March 14, 2007.



**Figure 2** Histopathological examination of the lesion demonstrating nodular fasciitis with proliferation of bland-looking fibroblasts, extravasated red cell, and one mitotic figure in the myxoid background. (Hematoxylin-eosin stain; original magnification,  $\times 200$ .)

from 0.4 to 8 cm with a mean of 1.9 cm. Five patients reported pain; 5 patients presented bleeding, and 2 of these patients got surface ulceration and one had malodorous discharges. The duration of symptoms lasted from a few days to 36 months, with a mean of 5 months. The locations arranged mostly in the postauricular (19 patients) and preauricular areas (18 patients).

On the basis of the lesion's location, nodular fasciitis appears as one of three types: subcutaneous, intramuscular, and intermuscular (fascial) types. The subcutaneous type occurs 3 to 10 times more commonly than the other subtypes and presents as a subcutaneous mass.<sup>2</sup> Sixty-five percent of cases in the study by Lester and Thompson<sup>3</sup> were dermal (superficial) based. Our case described here is also subcutaneous type.

Nodular fasciitis may be mistaken for a malignant neoplasm clinically and/or histologically.<sup>1</sup> The differential diagnosis is made more difficult by the rarity of the lesion at this site. Its rapid growth, rich cellularity, high mitotic activity, and infiltrative borders make it easily misdiagnosed as a mesenchymal malignancy.<sup>4</sup> In addition, no pathognomonic finding can be made using CT and magnetic resonance imaging.<sup>2</sup>

Differential diagnoses include a number of benign and malignant entities of salivary gland or soft tissue origin involving the parotid region, such as neurogenic tumor,

minor salivary gland tumor, dermoid or epidermoid, hemangioma, sarcoidosis, aggressive fibromatosis, dermatofibroma, fibrosarcoma, and malignant fibrous histiocytoma.<sup>2</sup> A clear basis of what histopathology and clinical symptoms point toward nodular fasciitis can lead not only to expedient diagnosis of nodular fasciitis but also can eliminate inappropriate procedures resulting from the common misdiagnosis.<sup>4</sup> The lesion is curable with adequate surgical treatment. There was a higher local recurrent rate (9.3%) in the auricular region than in other regions (1%-2%). The reason for the higher recurrent rate was contributed to the difficulty in obtaining complete surgical excision because of the anatomy of the auricular regions.<sup>3</sup> Recurrence is rare, and once it happens, a malignant lesion must be reconsidered.<sup>4</sup>

## AUTHOR INFORMATION

From the Departments of Otolaryngology (Drs Huang and Lee) and Pathology (Dr Lin), Taipei Medical University Hospital, Taipei Medical University.

Corresponding author: Fei-Peng Lee, MD, Professor, Department of Otolaryngology, Taipei Medical University Hospital, 252 Wu-Hsing Street, Taipei, 110, Taiwan.

E-mail address: fplee@tmu.edu.tw.

## FINANCIAL DISCLOSURE

None.

## REFERENCES

1. Abendroth CS, Fraunhoffer EE. Nodular fasciitis of the parotid gland. Report of a case with presentation in an unusual location and cytologic differential diagnosis. *Acta cytologica* 1995;3:530-4. (Grade C).
2. Kim ST, Kim HJ, Park SW, et al. Nodular fasciitis in the head and neck. CT and MR imaging findings. *Am J Neuroradiol* 2005;26:2617-23. (Grade C).
3. Lester DR, Thompson JC. Nodular fasciitis of the external ear region: a clinicopathologic study of 50 cases. *Ann Diagn Pathol* 2001;5:191-198. (Grade C).
4. Silva P, Bruce IA, Molik T, et al. Nodular fasciitis of the head and neck. *J Laryngol Otol* 2005;119:8-11. (Grade C).