

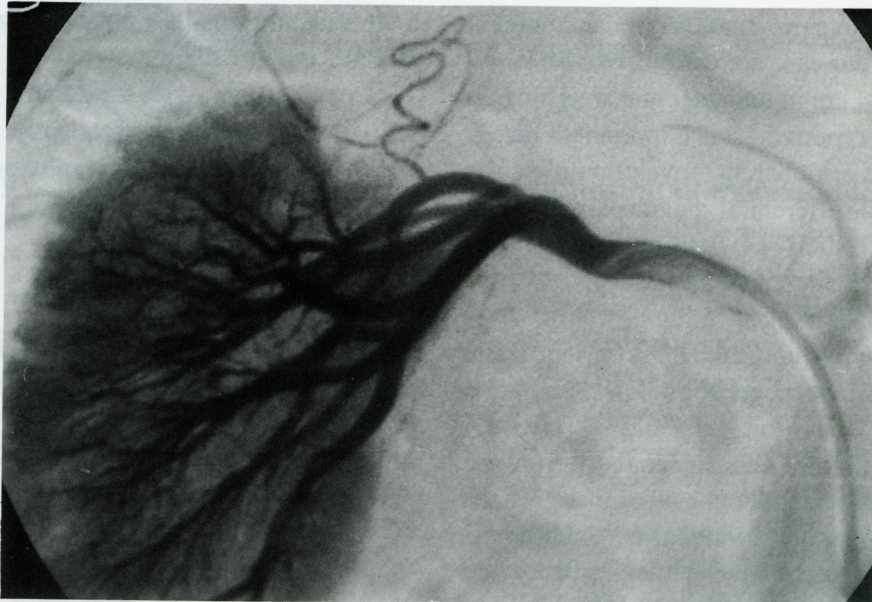Fig. 3. Selective right renal angiography demonstrating a hypervascular tumor above the right kidney with downward displacement of the right kidney.

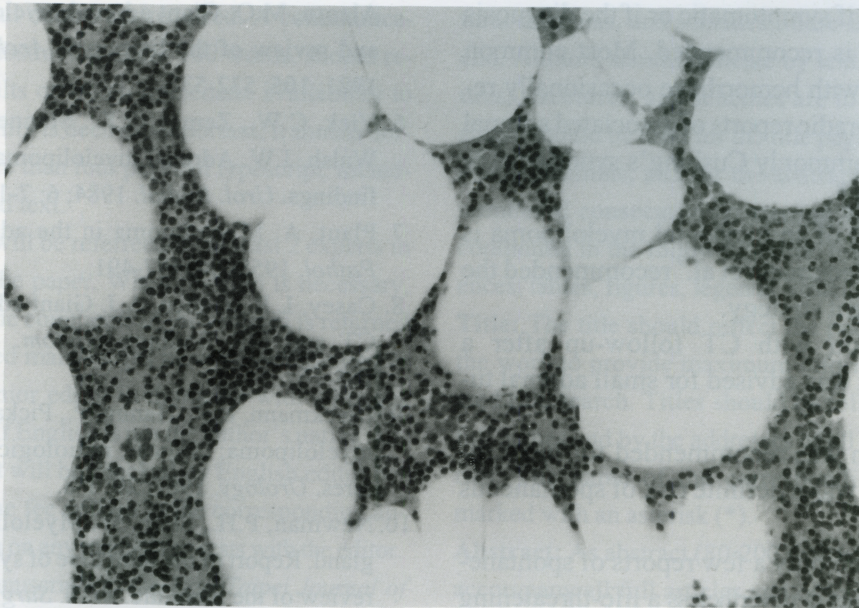


Fig. 4. Microscopic HE stain with 200x magnification showing mostly adipose tissue with foci of hemopoietic cells.

with nests of hemopoietic elements (Fig. 4), including precursors of myeloid, erythroid, and megakaryocytic cells. Residual adrenal tissue was present in the subcapsular region. The patient was well after surgery with no adverse effects.

DISCUSSION

Adrenal myelolipomas are rare, benign tumors consisting of mature fat and bone marrow elements. Most cases are unilateral and fairly small, usually less