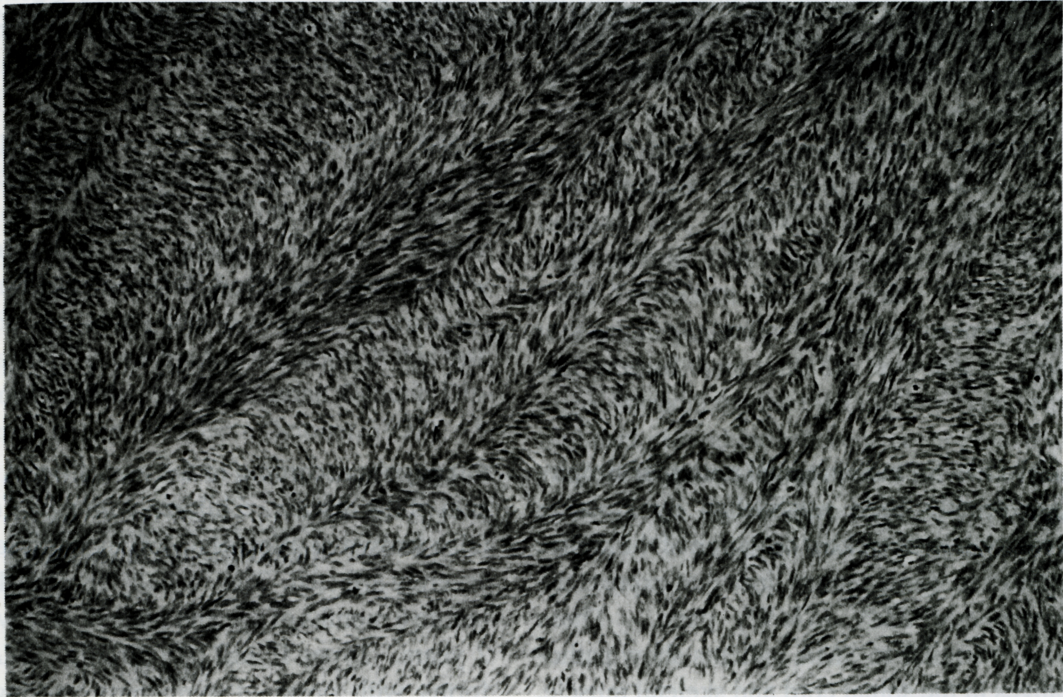

Impressive Image



Herringbone Pattern in Fibrosarcoma

This picture was taken under light microscopy from a soft tissue mass of the left thigh of a 75-year-old male patient. Relatively uniform spindle cells are arranged in a distinct interlacing fascicular pattern (or herringbone pattern). This is a distinct pattern for diagnosis of well-differentiated fibrosarcoma. It looks like a wave of billowing wheat buffeted by a gust of wind.

Chien-Jui Cheng M.D

Department of Pathology, School of Medicine,
Taipei Medical College, Taipei, Taiwan

©1999, Taipei Medical College,