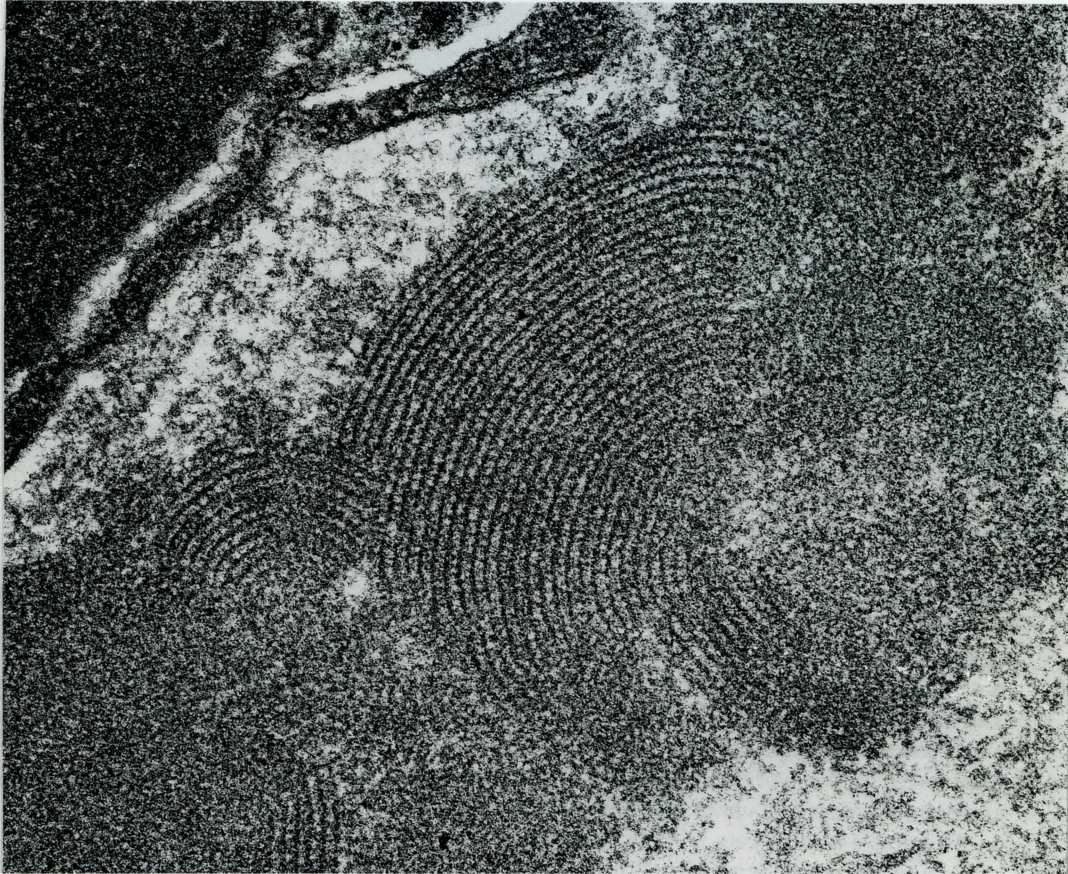

Impressive Images



Lupus Nephritis

A 15-year-old male with a history of suspected lupus has developed bilateral lower leg edema for the last two years. Biopsy was performed to evaluate the renal involvement.

The electron microscopic features are characteristic. The electron-dense deposits are mostly granular in appearance, but the organized deposits exhibiting various figures are noticeable. Among them, the fingerprint substructure is most striking. It consists of parallel curved arrays that display dark bands alternating with light bands. Although this feature is eye-catching, it is, however, not unique to lupus. The possibility of cryoglobulinemia should always be entertained.

Chin-Yuan Tzen, M.D., Ph.D., F.C.A.P.^{a,b} Shiu-Ching Chen^b

^aDepartment of Pathology and ^bDepartment of Medical Research

Mackay Memorial Hospital,

Taipei 104, Taiwan.