

A Virtual Bronchoscopy with Color-mapped Wall Thickness

Sang Joon Park²⁾³⁾, Jong Hyo Kim^{*1)2)3)}, Jin Mo Goo¹⁾³⁾, Kwang Gi Kim¹⁾³⁾, Sang Ho Lee²⁾³⁾

¹⁾Department of Radiology, ²⁾Department of Radiation Applied Life Science,

³⁾Institute of Radiation Medicine,

Seoul National University College of Medicine, Seoul, Korea

Correspondence: kimjh@radcom.snu.ac.kr

Abstract

The tracheo-bronchial tree as part of the lung is part of one of the most important organs of the human body. Even if the recent technical development improved resolution and scan velocity related to computed tomography (CT), it cannot image smaller airways and distally to obstructions, which is a limit in CT images besides real bronchoscopy. In this paper, we demonstrate a new method for wall thickness-mapped virtual bronchoscopy through measurement of airway wall thickness with a proposed algorithm. We present an enhanced virtual bronchoscopy that allows assessment of wall thickness during the virtual fly-through using below steps. Firstly, the airway trees are segmented, and then airway center lines and bifurcation points at each generation are acquired with morphological analysis. Then, we can calculate every wall thickness of each generation of the volumetric airway tree by using a proposed method based on vector analysis with perpendicular plane to airway. Finally, our own software visualizes color-mapped virtual bronchoscopy that reflects airway wall thickness, flying through the inner path of airway. Using CT scans of human cases, we present results showing that this new approach is convenient, accurate, automatic and well-visual in estimating airway wall thickness. Our proposed method can provide pre-operative planning of the intervention for lung surgery with enhanced functional virtual bronchoscopy as a complementary tool for clinical diagnosis and several diseases of airway.

1. Introduction

The primary role of the lungs is gas exchange. The lungs exchange air with the external environment via the pulmonary airways. The tracheo-bronchial tree (airways) as part of the lung is part of one of the most important organs of the human body. The airways are organized as a branching network of tubes that become narrower, shorter, and more numerous as they penetrate deeper into the lung. Air enters the pharynx through the nose and is conducted to the lungs through the trachea. The trachea divides into two main branches, the left and right bronchi, which enter into the right and left lungs. The geometry of the airway tree is approximately bipodial, i.e., at each branch division (a *branchpoint* or *bifurcation*), the

parent airway branches into two child airways. The trachea, commonly defined as airway tree branch generation zero, is the root of the airway tree. As a parent airway splits into two or more child airways, a new generation of the tree is formed. The trachea is typically 1–2 cm in diameter in a normal adult. By generation three of the airway tree, the airways, called bronchioles, range in size from 1 to 5 mm in diameter. The branches from the trachea to the end of terminal bronchioles make up the first 17 generations of the airway tree. Beyond generation 17, the airways continue to branch and lead to the alveolar ducts, and ultimately terminate at the alveolar sacs, the site of gas exchange [1]-[3].

Inhaled air is distributed to the alveolus where oxygen and carbon-dioxide exchange between air and blood takes place. The tracheo-bronchial tree is complemented by a system of pulmonary venous and arterial blood vessels which transports the blood to and from the heart into the lungs.

Several pathologies can jeopardize a sufficient lung function. Among them are tumors, pulmonary embolism, collapse of the lungs (atelectasis), pneumonia, emphysema, asthma, and many more. For a proper diagnosis and treatment, the respective pathologies need to be identified and in some cases quantified. Furthermore, lung surgery requires a pre-operative planning of the intervention. Currently, this is done using a combination of computed tomography (CT) as a tool for morphological imaging of the whole lung parenchyma, and bronchoscopy as an interventional tool for inspection of the central airways and deriving tissue samples. Due to the recent technical development improving resolution and scan velocity, CT might be an promising alternative to bronchoscopy. Even because it images smaller airways and distally to obstructions, which is a limit in real bronchoscopy [4].

Quantitative analyses can be performed on the three-dimensional (3-D) airway tree to evaluate tree structure and function using a CT imaging [5], [6]. Tree geometry can be used to help physicians assess pathological conditions, such as stenoses, bronchiectasis, and tumors. For instance, an unusual reduction in the size of the airway lumen at a particular level in the airway tree may indicate a possible stenosis and an abnormal dilation of the airway represents bronchiectasis. Since an image-based analysis of the airway tree can provide precise airway size information, CT imaging can be used to



guide airway stent design [7]. In addition, unlike bronchoscopic examination of the airways, image-based analysis can provide valuable information about the condition of airways distal to a stenosis. Longitudinal analysis of the 3-D airway tree can also play a role in tracking disease. Changes in a disease process or response to therapy can be tracked over time by using the airway as a “road map” to register regions of interest. Thus, analysis of the 3-D airway structure can provide a more complete understanding of physiologic and patho-physiologic conditions.

In this contribution, we introduce our own developed the virtual bronchoscopy system to perform virtual inspections of tracheo-bronchial trees. It provides an interactive visualization of color-mapped wall thickness through measurement of airway wall thickness. The airway trees are segmented, and then airway center lines and bifurcation points at each generation are acquired with morphological analysis. Then, we can calculate every wall thickness of each generation of the volumetric airway tree by using a proposed method based on vector analysis with perpendicular plane to airway. Finally, our own software visualizes color-mapped virtual bronchoscopy that reflects airway wall thickness, flying through the inner path of airway.

2. Materials and Methods

Our proposed methods have been applied to 8 patients, 4 with normal and 4 with COPD (chronic obstructive pulmonary disease) cases. In each patient, 16 channel CT scan was acquired at the maximal inspiration and the dataset included the thorax from the trachea to the diaphragm since our method is focused on the airway. All our implementation and test were performed on an Intel Pentium IV PC containing 3.0 GHz and 1.0 GB of main memory. The image size of all patient datasets is 512×512.

2.1 Segmentation

We used 3-D confidence connected region growing (CCRG) method to extract lower and upper airways of the bronchi. This segmentation method is based on the NLM Insight Segmentation and Registration Toolkit (ITK). The algorithm is left to establish a criterion to decide whether a particular pixel should be included in the current region or not, because the most important thing is visiting neighboring pixels. The criterion used by the CCRG is based on simple statistics of the current region. First, algorithm computes the mean and standard deviation of intensity values for all the pixels currently included in the region. A user-provided factor is used to multiply the standard deviation and define a range around the mean. Neighbor pixels whose intensity values fall inside the range are accepted and included in the region. When no more neighbor pixels are found that satisfy the criterion, the algorithm is considered to have finished its first iteration. At this point, the mean and

standard deviation of the intensity levels are recomputed using all the pixels currently included in the region. This mean and standard deviation defines a new intensity range that is used to visit current region neighbors and evaluate whether their intensity falls inside the range. This iterative process is repeated until no more pixels are added or the maximum number of iterations, user defined value, is reached. As the pixel pointer walks, the output segmented image refer to corresponding pixel in the input image. As long as the number of iteration is increased, the pixel is added to the output segmentation and its neighbors become candidates for the pointer to walk.

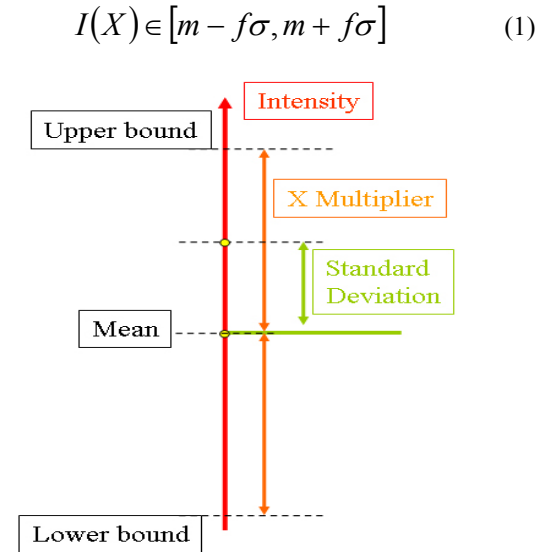


Figure 1. Schema of CCRG

where m and σ are the mean and standard deviation of the region intensities, f is a factor defined by the user, $I()$ is the image and X is the position of the particular neighbor pixel being considered for inclusion in the region.

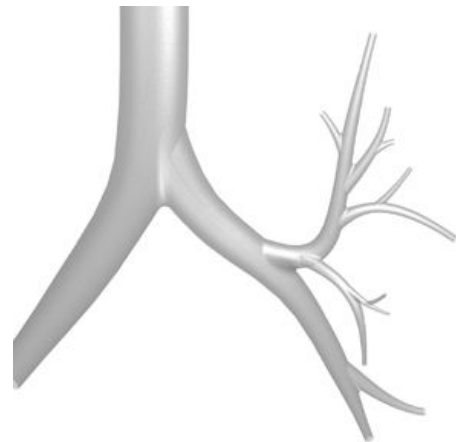


Figure 2. Segmented airway model



2.2 Center line extraction

After segmentation of the airways was completed, a 3D skeletonization algorithm [8] was used to obtain the center line of the extensive airway network.

Erosion of the volume layer by layer from the outermost surface was completed using a geometry and connectivity preserving fully-parallel 3D thinning algorithm until only the center line was left. This process preserved the geometry of the original object and preserved important details such as small airway bifurcations. There were some preserving conditions that ensured the algorithm would not delete the end points of airway segments. Preservation of connectivity is very important in 3D algorithms so that large breaks do not occur, which can lead to disconnected airway segments.

This particular algorithm used a set of 38 deleting templates which were created using simple reflections and rotations around four classes of core templates [8]. Each template was applied to every object voxel within the segmented volume and if it fit, then that voxel was marked for deletion. After all voxels that satisfied a particular template were marked, they were deleted if they were not a line-end voxel. Then the next iteration began until no more voxels satisfied a particular template, and thus no more voxels were deleted.

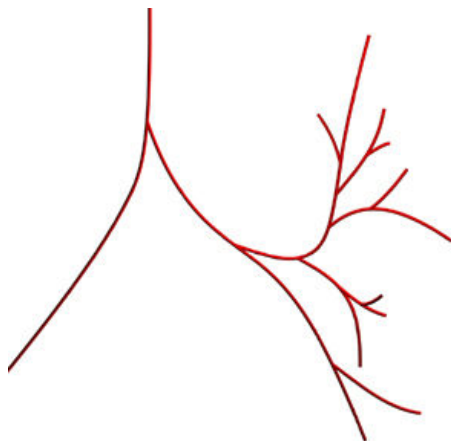


Figure 3. Extraction of airway center line

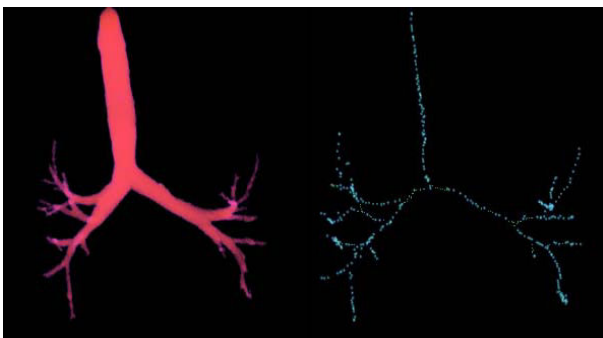


Figure 4 Segmented airway with CCRG and center line

2.3 Wall thickness measurement

High Resolution X-ray computed tomography (CT) [HRCT] based imaging and quantitative measurement of peripheral bronchial airway geometry provides a valuable tool and information for assessing regional pulmonary physiology and pathophysiology.

Measurements of bronchial tree airway geometry can be used to evaluate and track the progression of disease affecting the airways, such as asthma, COPD and cystic fibrosis, and to assess the efficacy of new therapeutic approaches. Even though, the larger airways have a little effect on the airflow resistance than small airways, thickening of large airways may be a surrogate for small airway abnormalities. It is possible that the same pathophysiologic process, which results in excessive obstruction of small airways, also occurs in the larger airways. Although increased airway wall thickness in the larger airways may have little functional consequence, the ability to measure thickening using CT could prove to be a useful predictor of small airway pathology and may allow for phenotypic stratification of patients who have COPD into parenchymal - and airway- predominant categories [9].

These measurements are used to identify three distinct changes in the respiratory pathways, airway size, obstructions, and airway wall thickness. These changes reflect specifically the morphology of the airways. The changes of airflow resistance can be inferred from airway size and obstructions. And we can predict or infer the pathological process from airway wall thickness.

There has been considerable interest in measuring intrathoracic airways in two or three-dimensional (3-D) sets of slices from volumetric X-ray CT. A popular airway measurement method uses the "halfmax" criteria, in which the gray level at the airway wall is estimated to be halfway between the minimum and maximum gray levels along a ray crossing the edge. However, because the scanning process introduces blurring, the half-max approach may not be applicable across all airway sizes [10]. For this reason, new sensitive and reliable methods for assessing alterations in regional lung structure and function are critically important for the investigation and treatment of pulmonary diseases.

We used a airway measurement via parameter estimation method. With pre-operated results, we applied image plane perpendicularly to airway. Then, we can calculate every wall thickness of each generation of the volumetric airway tree by using measurement via parameter estimation method. In our approach, we examine the gray-level profile of a ray crossing the airway wall and use a maximum-likelihood method to estimate the airway inner and outer radius.



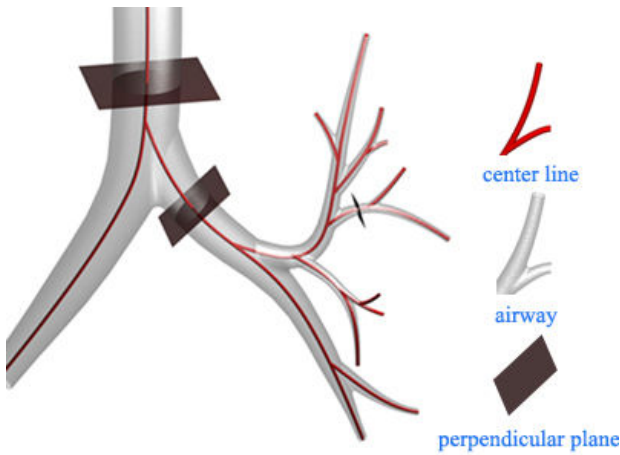


Figure 5 Quantitative analysis

2-D slices are re-sampled perpendicular to center line, inner border is detected, cross-sectional area, inner, and outer-radius are computed.

Fig. 6 shows a simple 2-D model of a single slice of an ideal airway cut perpendicular to the airway. The airway centroid is at the origin, and the airway has inner radius l_i and outer radius l_o ($l_i < l_o$). The density of the airway wall is unity and the density of the lumen (air) is zero. The airway is surrounded by tissue of constant density (typically, $0 \leq \alpha < 1$), which models the lung parenchyma.

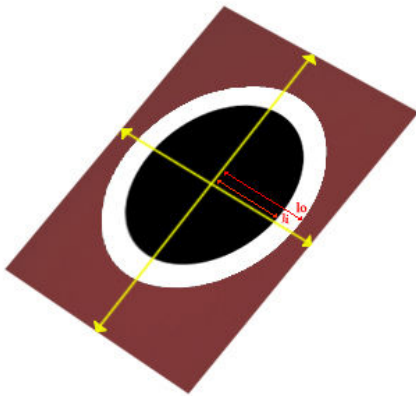


Figure 6. Ideal 2-D airway model with inner radius l_i and outer radius l_o

Density of airway wall (white) is unity; density of airway lumen (dark gray) is zero; tissue external to airway (light gray) has mean density α (typically, $0 \leq \alpha < 1$).

2.4 Color-mapped virtual bronchoscopy

Finally, our own software visualizes color-mapped virtual bronchoscopy that reflects airway wall thickness, flying through the inner path of airway.

For the virtual endoscopic exploration, usually we assume a viewpoint inside a bronchi. As usual, for the actual virtual bronchoscopy, we start in the trachea (Fig.

12) and traverse the tracheobronchial tree (Fig. 13 and Fig. 14) to the target region of interest using an obtained path.

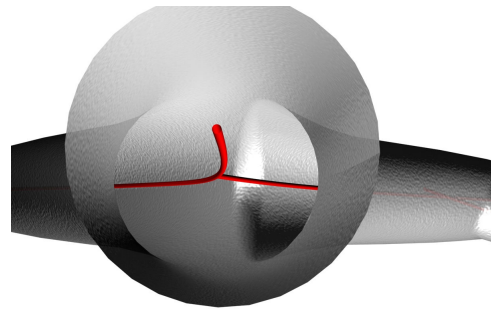


Figure 7. Model of flying through

3. Results

In general, virtual bronchoscopy is a valuable tool for the localization and measurement of stenosis for treatment planning.

We have described a new method for wall thickness-mapped virtual bronchoscopy through measurement of airway wall thickness with a proposed algorithm for 3-D X-ray CT images of the lungs. We presented an enhanced virtual bronchoscopy that allows assessment of wall thickness during the virtual fly-through using below steps. Firstly, the airway trees are segmented, and then airway center lines and bifurcation points at each generation are acquired with morphological analysis. Then, we can calculate every wall thickness of each generation of the volumetric airway tree by using a proposed method based on vector analysis with perpendicular plane to airway. Finally, our own software visualized color-mapped virtual bronchoscopy that reflects airway wall thickness, flying through the inner path of airway.

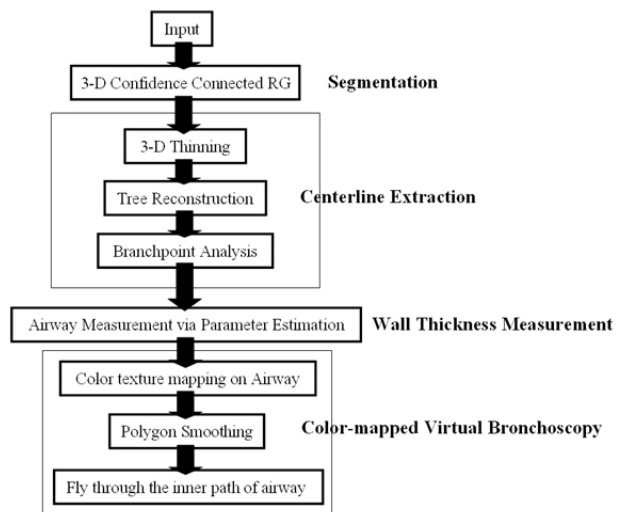


Figure 8. Flowchart of the color-mapped virtual bronchoscopy

4. Discussion

Airway tree segmentation in CT images is a challenging problem because of the complex anatomy and the limitations in image quality inherent to CT image acquisition. Despite improvements in image quality accomplished by utilizing thin slices and the high spatial resolution reconstruction algorithm in CT images, if the airway long axis is not perpendicular to the imaging plane, airway segmentation is limited by partial volume effects [11]. Contrast in a CT image is determined by the differential absorption of X-rays by neighboring structures. The airway wall separates the lumen of the airway from the surrounding lung tissue and, thus, we would expect a high contrast border around the lumen. But, if the airway orientation tilts toward the image plane, the density values inside the airway lumen increase due to partial volume averaging of air and airway wall. The apparent airway lumen density increases substantially with decreasing airway diameter due to partial volume effects as well. These partial volume effects reduce the contrast between the wall and lumen, making airway wall detection difficult.

5. Conclusion

Using CT scans of human cases, we presented results showing that this new approach is convenient, accurate, automatic and well-visual in estimating airway wall thickness. Our proposed method can provide pre-operative planning of the intervention for lung surgery with enhanced functional virtual bronchoscopy as a complementary tool for clinical diagnosis and several airway diseases.

6. References

- [1] M. G. Levitzky, *Pulmonary Physiology*. New York: McGraw-Hill, 1999.
- [2] J. B. West, *Respiratory Physiology. The Essentials*, 4th edition. Baltimore, MD: Williams and Wilkins, 1990.
- [3] J. F. Murray, *The Normal Lung*. Philadelphia, PA: Saunders, 1986.
- [4] D. Mayer and D. Bartz and S. Ley and S. Thust and C. Heussel and H. Kauczor and W. Straßer, "Segmentation and Virtual Exploration of Tracheo-Bronchial Trees", in: *Proc. of Computer Assisted Radiology and Surgery*, 2003, pp. 35-40.
- [5] W. E. Higgins, K. Ramaswamy, R. D. Swift, G. McLennan, and E. A. Hoffman, "Virtual bronchoscopy for three-dimensional pulmonary image assessment: State of the art and feature needs," presented at the RSNA Annu. Meeting, Chicago, IL, 1998, pp. 761-778
- [6] E. A. Hoffman and G. McLennan, "Assessment of the pulmonary structure—Function relationship and clinical outcomes measures: Quantitative volumetric CT of the lung," *Acad. Radiol.*, 1997, vol. 4, no. 11, pp. 758–776.
- [7] G. McLennan, S. Shamsolkotabi, and E. A. Hoffman, "Assessment of major airway obstruction using image analysis

of digital CT information," *Proc. SPIE*, 1996, vol. 2709, pp. 197–208.

[8] Ma C M and Sonka M, "A fully parallel 3D thinning algorithm and its applications *Comput. Vis. Image Underst.*, 1996, Vol. 64, no. 3, pp. 420–33

[9] Nakano Y, Wong JC, de Jong PA, et al. The prediction of small airway dimensions using computed tomography. *Am J Respir Crit Care Med* 2005;171:142–146.

[10] Reinhardt, J.M., N.D. Dsouza, and E.A. Hoffman, "Accurate measurement of intrathoracic airways", *IEEE Trans. Med. Imag.* 1997, pp. 820-827

[11] J. M. Reinhardt, N. D. D'Souza, and E. A. Hoffman, "Accurate measurement of intra-thoracic airways," *IEEE Trans. Med. Imag.*, 1997, vol. 16, pp. 820–827, Dec.



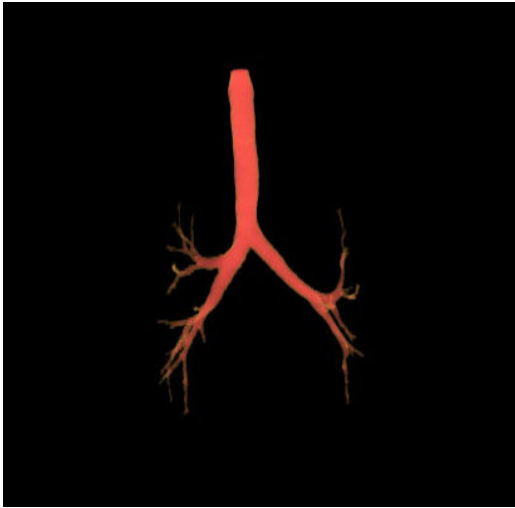


Figure 9. Segmented airway with CCRG in normal case

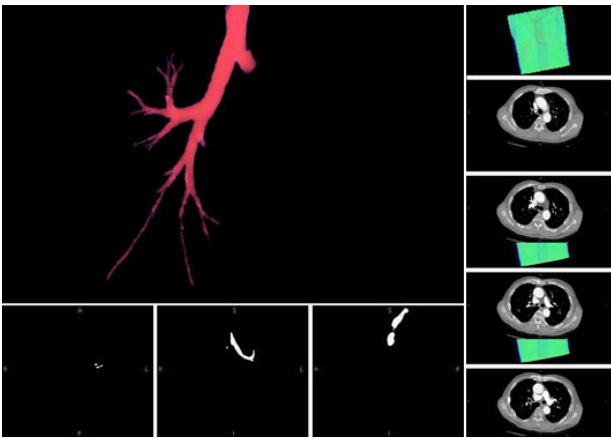


Figure 10. Segmented airway with CCRG in COPD case

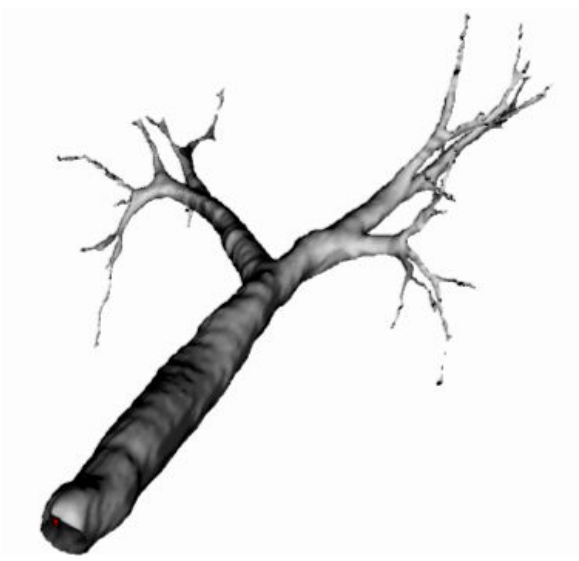

Figure 11. Airway using geometric rendering




Figure 12. Virtual bronchoscopy
View in trachea down to main bifurcation.

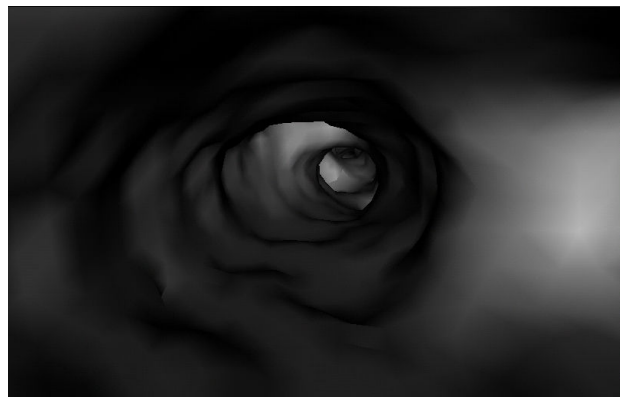


Figure 13. Virtual bronchoscopy
Lower airways

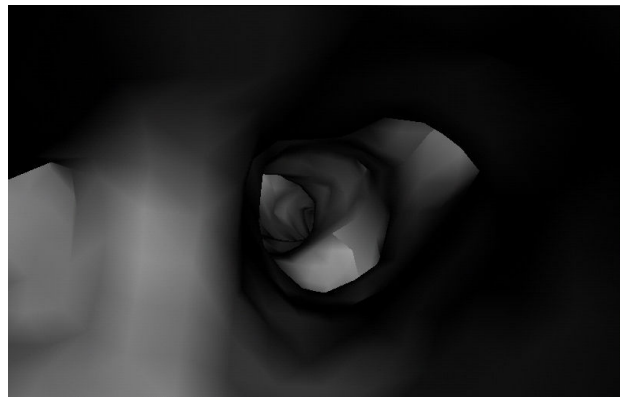


Figure 14. Virtual bronchoscopy
Bifurcation of the bronchioles

