

Case report

## MRI of hemangioblastoma in the conus medullaris

Chia-Yuen Chen<sup>a,b</sup>, Pao-Huan Chen<sup>a</sup>, Min-Szu Yao<sup>b</sup>,  
Jan-Show Chu<sup>c</sup>, Wing P. Chan<sup>a,b,\*</sup>

<sup>a</sup> Department of Radiology, School of Medicine, Taipei Medical University,  
Taipei 116, Taiwan, Republic of China

<sup>b</sup> Department of Radiology, Taipei Medical University-Municipal Wan Fang Hospital,  
Taipei 116, Taiwan, Republic of China

<sup>c</sup> Department of Pathology, School of Medicine, Taipei Medical University,  
Taipei 116, Taiwan, Republic of China

Received 31 July 2006; received in revised form 6 August 2007; accepted 15 August 2007

### Abstract

Hemangioblastoma of the conus medullaris with MRI has not been reported before. A 75-year-old man had a history of falling due to weakness of his left lower limb. MRI revealed a well-defined oval mass in the conus medullaris. The tumor had an isointense signal relative to spinal cord on T1-weighted images, hyperintense signal areas intermixed with punctate spots of hypointensity on T2-weighted images, and heterogeneous obvious enhancement on gadolinium-enhanced T1-weighted images. Associated abnormally tortuous vessels were noted in the dura proximal to the tumor. Histological findings were compatible with the diagnosis of hemangioblastoma. Hemangioblastoma should be included in the differential diagnosis in patients with an enhancing tumor and adjacent engorged vessels of the spinal cord.

© 2007 Elsevier Ltd. All rights reserved.

**Keywords:** Conus medullaris; Hemangioblastoma; Magnetic resonance imaging (MRI); Spinal cord tumors

### 1. Introduction

Hemangioblastomas are benign vascular tumors that may arise throughout the neuraxis. The tumors most commonly occur in the cerebellum [1]. Spinal cord hemangioblastoma is uncommon, comprising 1.6–5.8% of all spinal cord tumors and associated with Von Hippel Lindau syndrome in an estimated 32% [2]. Isolated hemangioblastomas of the spinal cord, especially of the lumbosacral region, are extremely rare [3]. One report suggested that the total number of all reported cases of hemangioblastoma of the cauda equina may be as low as 40, with few of these tumors having a demonstrated MRI appearance [4]. To our knowledge, hemangioblastoma of the conus medullaris with MRI has not been reported before.

We herein present a case of a 75-year-old man with MRI findings of an isolated hemangioblastoma of the conus medullaris.

### 2. Case report

A 75-year-old man suffered from low-back pain with radiation to the legs for many years. Difficulty in urination was noted. The patient received an L1 to L4 laminectomy due to lumbar spondylosis 5 years ago. He fell down because of his left lower limb weakness several days before this admission. Preoperative neurological examination revealed sacral analgesia, left thigh and calf muscle atrophy, and decreased muscle power and deep tendon reflex in the legs bilaterally. In a urodynamic study, a neurological bladder was also found.

MRI (1.5-T, Horizon LX, General Electric) of whole spine showed a well-defined mass in the conus medullaris of the spinal cord (Fig. 1A–D). The tumor exhibited isointensity on T1-weighted images, hyperintensity on T2-weighted images, and heterogeneous, obvious enhancement on gadolinium contrast-enhanced T1-weighted images. A peritumoral cystic component also was noted. Adjacent serpiginous flow voids, indicating enlarged vessels, were noted at the surface of the rostral cord. Spondylosis at the level of L4 with laminar defects was also noted.

The tumor in the conus medullaris was partially removed. L3 laminectomy was also performed for decompression of

\* Corresponding author at: Department of Radiology, Taipei Medical University-Municipal Wan Fang Hospital, 111 Hsing Long Road, Section 3, Taipei 116, Taiwan, Republic of China. Tel.: +886 2 2930 7930x1300; fax: +886 2 2931 6809.

E-mail address: [wingchan@tmu.edu.tw](mailto:wingchan@tmu.edu.tw) (W.P. Chan).

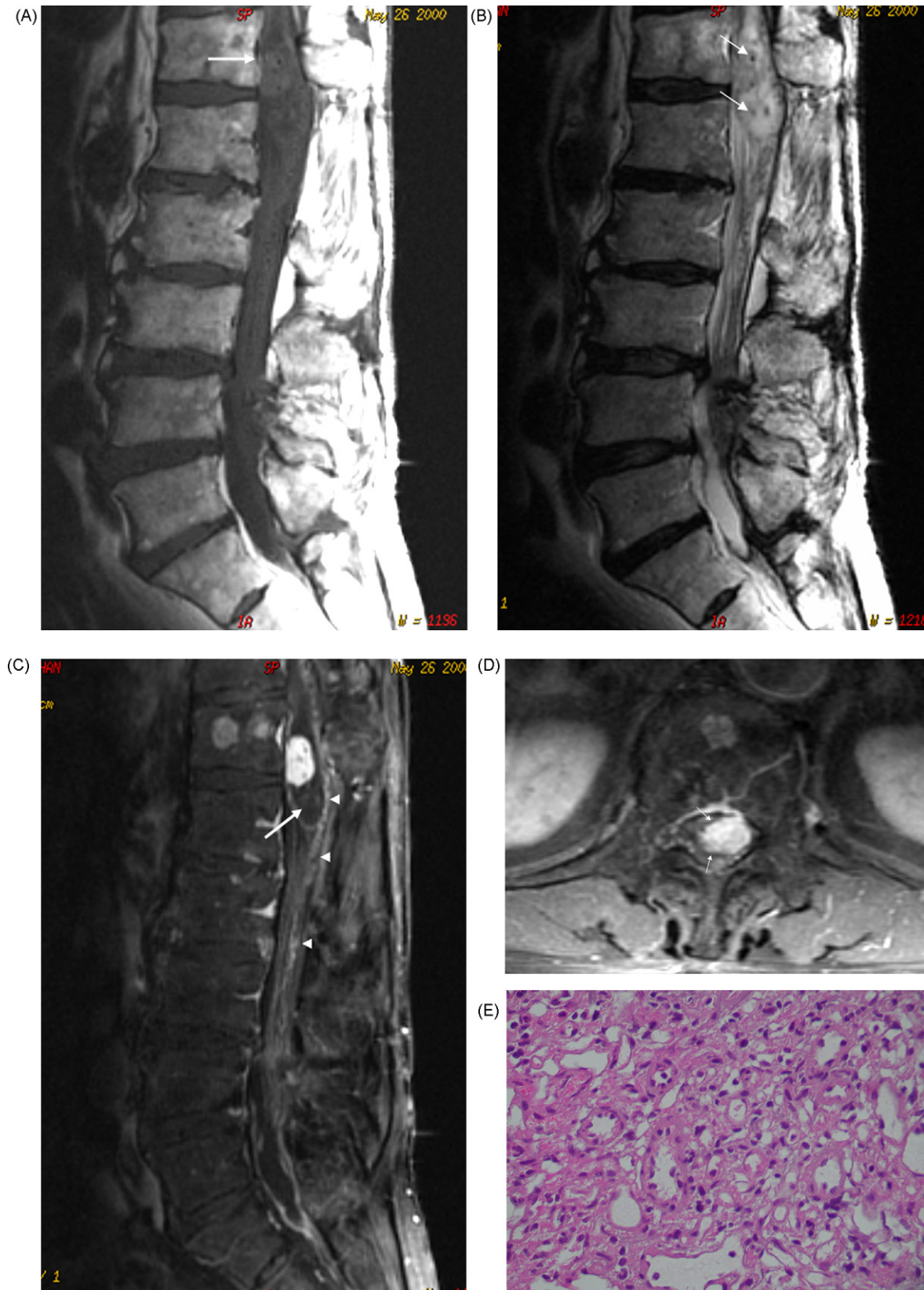


Fig. 1. (A) Sagittal T1-weighted MRI image (TR=400 ms, TE=12 ms) shows an isointense signal of the tumor (arrow) at the conus medullaris. (B) Sagittal T2-weighted image (TR=3000 ms, TE=121.8 ms) shows a hyperintense signal of tumor intermixed with signal void spots (arrows). (C) Sagittal gadolinium-enhanced T1-weighted image (TR=366.7 ms, TE=13.1 ms) shows heterogeneous enhancement of the tumor (arrow) with a peritumoral cystic component (curved arrow). Note extratumoral tortuous vessels (small arrows). (D) Axial gadolinium-enhanced fat saturation T1-weighted image (TR=650.7 ms, TE=13.6 ms) shows intramedullary location of the tumor (arrow) with obvious enhancement. (E) Photomicrograph shows that the tumor is composed of large vessels and numerous small capillaries (H&E, 400 $\times$ ).

spinal stenosis. Histological examination showed a hypervascular tumor composed of closely packed small vessels with capillary caliber and oval or spindle cells (Fig. 1E). The tumor was positive for vimentin and CD34 and negative for glial fibrillary acidic protein (GFAP); epithelial membrane antigen (EMA) staining was noted. Histological findings were compatible with the diagnosis of hemangioblastoma in the conus medullaris.

The patient had much improvement of the low-back pain after surgery. No progression of motor or sensory deficits was noted. However, symptoms of neurological bladder persisted for months.

### 3. Discussion

Isolated hemangioblastomas of the lumbosacral spinal cord are rare [3]. Browne et al. [5] reviewed 85 patients with hemangioblastomas of the spinal cord, solitary tumors in 79% of patients, and 51% in the thoracic region, 41% in the cervical region, and only 8% in the caudal region of the cord. Guidetti and Fortuna [6] reported that 27 of 29 intramedullary hemangioblastomas were cervical and/or thoracic and only one occurred at the conus.

MRI is considered as the diagnostic procedure of choice for spinal cord tumors [3,7]. With its multiplanar capabilities and high-contrast resolution, MRI allows identification and characterization of lesions in a noninvasive fashion. Ninety percent of the spinal cord tumors are astrocytoma and/or ependymoma [7]. Spinal cord astrocytomas most commonly occur in children and only 5% of them occur in the filum terminale [8]. Ependymomas occur often in adults, accounting for 60% of spinal cord tumors. Most of these tumors appear in the region of the conus and cauda equina [7]. Suspected spinal cord metastasis usually has a known primary cancer history and frequently involves the cervical or thoracic region [9]. Spinal cord astrocytoma and metastasis can be roughly excluded by tumor location, the patient's age and no clinical history of malignancy. Ependymoma, however, cannot be excluded from the differential diagnosis.

On MRI images, ependymomas are clearly enhancing lesions with an enhancing border, usually sharply marginated, and lying centrally in the spinal cord [7,10]. These tumors have low to high signal intensity on T1-weighted images, high signal intensity on T2-weighted images, and heterogeneous to homogeneous enhancement on gadolinium-enhanced images [10]. Hemosiderin is occasionally present at the periphery of the lesions, with rostral and caudal cysts [10]. However, neither astrocytoma nor ependymoma is likely to have prominent vessels [2].

Hemangioblastomas usually show enlargement of the spinal cord are associated with a cyst [7,11]. Fifty-five percent of hemangioblastomas of the spinal cord associated with cyst or syrinx [2]. Less frequently, serpiginous flow voids are present, indicating vessels [2,7,11]. Contrast-enhanced images can show one or more intensely enhancing nodules, which may be in the cyst wall or separate [7,11]. Spinal cord hemangioblastomas larger than 2.4 cm are often accompanied by vascular flow voids, in contrast to homogeneous enhancement of smaller hemangioblastomas [12]. In our case, the final diagnosis was

not correctly made before operation because of its uncommon location. In retrospect, the adjacent serpiginous flow voids were the only clue to the correct diagnosis.

Spinal cord hemangioblastoma may occur as a component of von Hippel-Lindau syndrome, accounting for 32% of these patients [2]. Patients with hemangioblastoma occur with a mean age 30, whereas those patients with von Hippel-Lindau syndrome may present earlier. There was no difference in MRI appearance of hemangioblastoma in patients with or without von Hippel-Lindau syndrome, except for multiplicity and higher percentage of smaller tumors in patients with von Hippel-Lindau syndrome [12].

Spinal cord hemangioblastomas are discrete and noninfiltrating lesions and generally can be completely removed at surgery [13]. The treatment of choice is total surgical removal using microtechniques, similar to that for resection of spinal arteriovenous malformation, without injury to the spinal cord even for intramedullary tumors [11–14]. Radiosurgery is usually not considered because hemangioblastomas are generally insensitive to radiation. However, only one intramedullary hemangioblastoma of the spinal cord has been reported to be treated with irradiation [15].

In summary, we present a rare case of an isolated hemangioblastoma in the conus medullaris. Hemangioblastoma should be included in the differential diagnosis in patients with an enhancing tumor and adjacent engorged vessels in any part of the spinal cord.

### References

- [1] Yachnis AT. Capillary hemangioblastoma. In: McLendon RE, Rosenblum MK, Bigner DD, editors. *Russell and Rubinstein's pathology of tumors of the nervous system*. 7th ed. London: Hodder Arnold; 2006. p. 489–507.
- [2] Baker KB, Moran CJ, Wippold 2nd FJ, et al. MR imaging of spinal hemangioblastoma. *AJR Am J Roentgenol* 2000;174:377–82.
- [3] Michaud LJ, Jaffe KM, Benjamin DR, Stuntz JT, Lemire RJ. Hemangioblastoma of the conus medullaris associated with cutaneous hemangioma. *Pediatr Neurol* 1988;4:309–12.
- [4] Rohde V, Voigt K, Grote EH. Intra-extradural hemangioblastoma of the cauda equina. *Zentralbl Neurochir* 1995;56:78–82.
- [5] Browne TR, Adams RD, Roberson GH. Hemangioblastoma of the spinal cord: Review and report of five cases. *Arch Neurol* 1976;33:435–41.
- [6] Guidetti B, Fortuna A. Surgical treatment of intramedullary hemangioblastoma of the spinal cord: report of six cases. *J Neurosurg* 1967;27:530–40.
- [7] Lowe GM. Magnetic resonance imaging of intramedullary spinal cord tumors. *J Neuro-oncol* 2000;47:195–210.
- [8] Osborn AG. *Diagnostic neuroradiology*. St. Louis: Mosby; 1994. p. 906.
- [9] Edelson RN, Deck MDF, Posner B. Intramedullary spinal cord metastasis. Clinical and radiographic findings in nine cases. *Neurology* 1972;22:1222–31.
- [10] Miyazawa N, Hida K, Iwasaki Y, Koyanagi I, Abe H. MRI at 1.5T of intramedullary ependymoma and classification of pattern of contrast enhancement. *Neuroradiology* 2000;42:828–32.
- [11] Xu QW, Bao WM, Mao RL, Yang GY. Magnetic resonance imaging and microsurgical treatment of intramedullary hemangioblastoma of the spinal cord. *Neurosurgery* 1994;35:671–6.
- [12] Chu BC, Terae S, Hida K, Furukawa M, Abe S, Miyasaka K. MR findings in spinal hemangioblastoma: correlation with symptoms and with angiographic and surgical findings. *AJNR Am J Neuroradiol* 2001;22:206–17.

- [13] Huang JS, Chang CJ, Jeng CM. Surgical management of hemangioblastomas of the spinal cord. *J Formos Med Assoc* 2003;102: 868–75.
- [14] Spetzler U, Bertalanffy H, Huffmann B, et al. Hemangioblastomas of the spinal cord and the brain stem: diagnosis and therapeutic features. *Neurosurg Rev* 1996;19:147–51.
- [15] Richardson RG, Griffin TW, Parker RG. Intramedullary hemangioblastoma of the spinal cord: Definitive management with irradiation. *Cancer* 1980;45:49–50.

**Chia-Yuen Chen** is Chief in Neuroradiology Section, Department of Radiology, Taipei Medical University-Wan Fang Hospital.

**Pao-Huan Chen** previously was medical student, School of Medicine, Taipei Medical University.

**Min-Szu Yao** is staff radiologist in Department of Radiology, Taipei Municipal Wan Fang Hospital.

**Jan-Show Chu** is Chairperson in Department of Pathology, School of Medicine, Taipei Medical University.

**Wing P. Chan** is Chairperson in Department of Radiology, School of Medicine, Taipei Medical University, and Chief in Department of Radiology, Taipei Medical University-Wan Fang Hospital.